

# Forensic dentistry case book 7: Family photos save the day

SADJ July 2016, Vol 71 no 6 p279

H Bernitz

The police were summoned to investigate the foul smell coming from a bachelor flat in a high rise building in Braamfontein, Johannesburg. After forcing their way into the flat, they found the body of a severely decomposed male. It was assumed that the deceased was the owner of the flat, but due to the extensive decomposition a visual identification was not possible. The deceased's children were all living aboard and were advised of the situation. From the state of the dentition, it was evident that the deceased had not visited a dentist for some time.

As no dental records could be found, other methods of identification had to be used. By chance a family member advised that she had a photo of her father. Generally "happy snaps" do not give sufficient detail to make a positive identification.

The following dental features were evident on examination of the dental status of the corpse (Figures 1 & 2):

1. Large diastema between the 11 and 21
2. 11, 12 and 13 present in the first quadrant
3. 21, 22 and 23 present in the second quadrant
4. 34 and 35 missing in the third quadrant
5. 34, 25 and 26 missing in second quadrant
6. Fractured amalgam filling in the 36

Noted the accumulation of maggots in the soft tissue.

Features visible in Figure 3 included:

1. Teeth 34 and 35 missing in the third quadrant
2. Filling visible in the 36

Figure 4 showed:

1. Large diastema present between front teeth
2. Teeth 21, 22 and 23 present
3. Teeth 24 and 25 missing

## DISCUSSION

It is generally not possible to get a positive identification from social "happy snaps". This case is unique in that not only do we see recognisable dental features in the front teeth, but there is a filled 36 which is visible in the photos provided. The presence of the diastema and the missing teeth allow us to match the general features present in the dentition of the victim with the general pattern present on the photo. The quality of the photos is such that small chips and minimal rotations would not be visible or provide sufficient detail to make a positive identification, but the general pattern association was sufficient for a positive match.<sup>1</sup>

## CONCLUSION

This case highlights the need to use whatever ante-mortem material is available to assist in the identification of otherwise unidentifiable corpses.

All names and places have been changed to protect the next of kin. Ethical approval has been granted by the Ethics Committee of the University of Pretoria to publish this case.

## References

1. Bernitz H. Concepts to elucidate the pattern-associated analysis of tooth marks in court. *J Dent Assoc S Afr* 2005;60: 62, 64-65

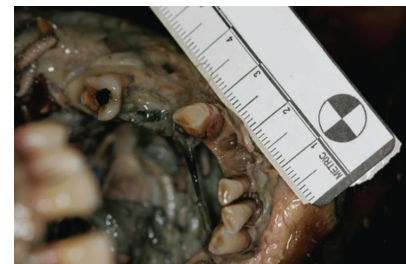

Figure 1: Lower jaw of deceased showing mesial remains of amalgam filling in the 36.

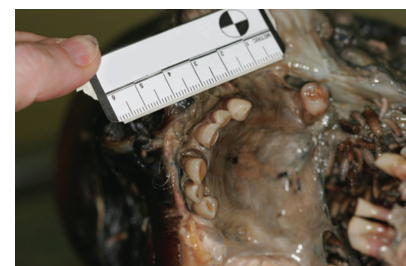

Figure 2: Upper jaw of deceased

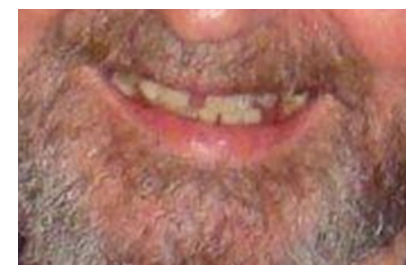


Figure 3: Photograph 1 received from family

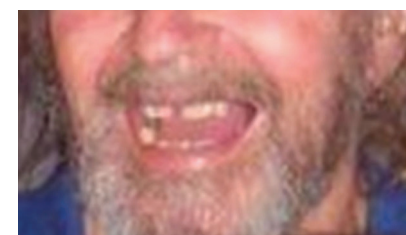

Figure 4: Photograph 2 received from family