

Oral medicine case book 76:

Methotrexate induced mucosal erosions and ulcerations

SADJ August 2017, Vol 72 no 7 p325- p327

M Negi¹, S Mulder Van Staden², H Holmes³, L Nel⁴

A 71-year-old male was referred from his general practitioner to the Oral Medicine Clinic at the University of the Western Cape, Oral Health Centre, Tygerberg campus, on account of a six-week history of recurrent oral ulceration.

The patient reported that his mouth and throat were painful and he had difficulty in swallowing food. Initially, the ulcers had persisted over the two weeks following the prescription of Dynexan®, Augmentin 1g BDS for 5 days, Andolex C® and Mucaïn mouthwash®, by his general practitioner. Subsequent referral to an ENT surgeon had resulted in confirmation of an extra-oesophageal reflux component. A PPI (proton-pump inhibitor), Gastrin®[®], was prescribed.

The patient disclosed that he had Type II diabetes, hypertension and had suffered a cerebrovascular accident (stroke) two years previously. Questioning by the ENT surgeon revealed that the patient had consulted a dermatologist who had prescribed methotrexate (MTX) to treat psoriasis. The patient did not use supplementary folic acid. The outcome of blood investigations, requested by the ENT surgeon, revealed bone marrow suppression as a result of the methotrexate usage. The patient was referred to his dermatologist with the recommendation that the medication be supplemented with folic acid.

Extra oral examination revealed the presence of a 10 mm scaly patch, surrounded by an erythematous margin, on the patient's right hand. Similar lesions were observed on the extensor surfaces of both legs.

The patient was edentulous with a loss of vertical dimension and did not wear any dentures. Diffuse, ill-defined erosions and ulcerations were present bilaterally on the buccal mucosa, upper and lower labial mucosa.

1. **Marwa Negi:** BChD, Division of Oral Medicine and Periodontics, Faculty of Dentistry, University of the Western Cape.
2. **Sune Mulder Van Staden:** BChD, MChD, Division of Oral Medicine and Periodontics, Faculty of Dentistry, University of the Western Cape.
3. **Haly Holmes:** BChD, MSc, MChD, Division of Oral Medicine and Periodontics, Faculty of Dentistry, University of the Western Cape.
4. **Leon Nel:** MBChB (Pret), FCS (SA), ORL (Ear Nose and Throat Surgeon), Private practice, Somerset West; Consultant, ENT Department Groote Schuur Hospital.

Corresponding author

Haly Holmes:

Division of Oral Medicine and Periodontology, University of the Western Cape Dental Faculty, Francie Van Zyl Drive, Tygerberg Campus.
Tel: 021 937 3102. E-mail: hholmes@uwc.ac.za

ACRONYMS

MTX: Methotrexate

The surfaces of the lesions were white to yellow in colour. The posterior soft palate had areas of irregular ulcerations and erosions, which contributed to the difficulty in swallowing.

A differential diagnosis of methotrexate-induced oral ulceration was proposed. The condition was exacerbated by the lack of folic acid supplementation, which contributed to the subsequent bone marrow suppression. The lymphocyte count, red cell count and platelet levels were $0.5 \times 10^9/L$, $2.8 \times 10^{12}/L$ and $63 \times 10^9/L$ respectively (Table 1).

Blood Investigation	Result	Normal Range
Lymphocyte count	$0.5 \times 10^9/L$	$1.00-4.00 \times 10^9/L$
Red blood cell count	$2.8 \times 10^{12}/L$	$4.5-5.9 \times 10^{12}/L$
Platelet levels	$63 \times 10^9/L$	$140-420 \times 10^9/L$
Hemoglobin	7.9 g/dL	11.5-16 g/dL
Hematocrit	0.25 L/L	0.40-0.50 L/L

DISCUSSION

Oral ulceration is a common side effect of various drugs.^{1,2} Direct contact may cause local hypersensitivity or chemical burn, or, less frequently, the complication is part of a complex reaction with cutaneous or systemic manifestations.¹

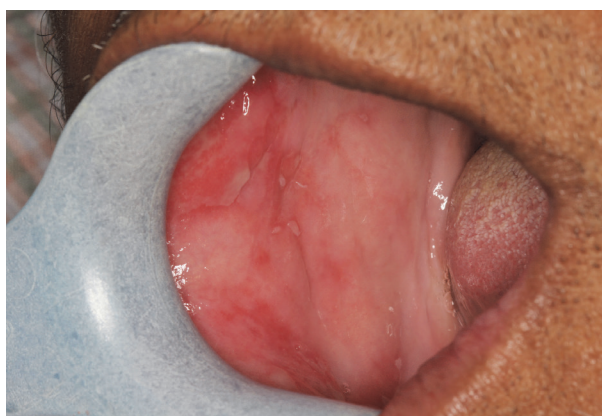


Figure 1: Methotrexate-induced mucosal erosions/ulcerations on the right buccal mucosa

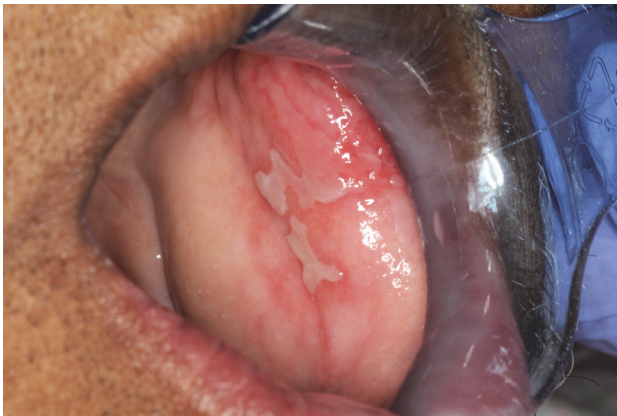


Figure 2: Diffuse erosions and ill-defined ulcerations on the left side buccal mucosa. The surface of the lesion was white to yellow in colour.

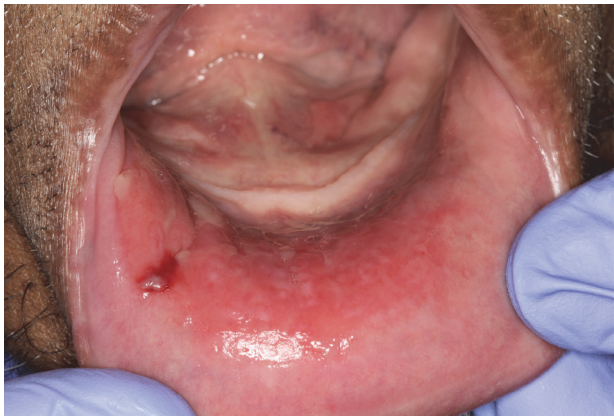

Figure 3: Diffuse erosions and ill-defined ulcerations on lower labial mucosa.

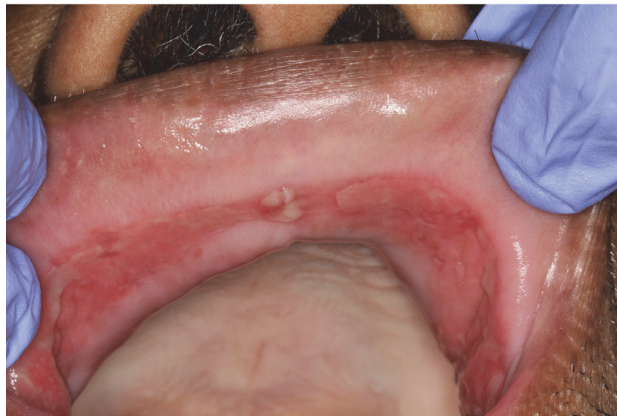


Figure 4: Diffuse erosions and ill-defined ulcerations on upper labial mucosa.

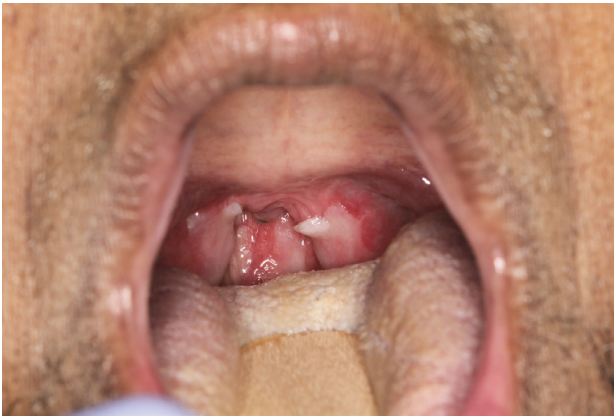

Figure 5: Posterior soft palate demonstrated irregular ulceration and erosions.

Drug induced oral ulcers are resistant to conventional therapies; but will heal rapidly following withdrawal or reduction of the dose of the suspect medication.¹ Recognition of the cause and subsequent diagnosis of these ulcerations is usually difficult, especially in patients on multiple drug regimens.^{1,3}

Medications likely to induce solitary oral ulcers are commonly prescribed in the management of rheumatoid, cardiac and psychiatric conditions.¹⁻³ (Table 2).

MTX is an antimetabolite, antifolate agent developed in 1948, used to treat certain forms of cancer. It is also commonly used to treat rheumatoid arthritis in both adults and juveniles and severe psoriasis.^{4,5} MTX interrupts the synthesis of both DNA and RNA and slows or stops the growth of rapidly dividing cells, including mucosal, cancer and bone marrow cells. MTX induces a deficiency of folate-dependent co-enzymes and suppresses the immune system.^{4,6} MTX is a bicarboxylic acid, a folic acid analogue that inhibits dihydrofolate reductase enzyme. The latter is required to reduce folate to an active form, which acts as a co-factor in the production of nucleic acids essential for DNA synthesis. Inhibition of this enzyme by MTX causes a reduction in DNA formation and cell turnover and is

responsible for both its therapeutic and the more common side effects, such as myelosuppression and mucositis.^{7,8} Psoriasis is a chronic, inflammatory, non-contagious skin condition usually affecting the skin of the elbows, knees, and scalp.^{9,10} The cells in the superficial skin layer multiply more quickly than normal, causing thickened areas of skin, and producing thick scaling plaque. It has a variable course with periodic periods of remission and exacerbation.⁹ Both biologic and non-biologic agents are used in its treatment. Non-biologics, such as MTX, suppress the immune system and are considered first-line treatments.¹¹ Biologics target certain aspects of the immune system contributing to the pathogenesis of psoriasis.^{11,12} These agents are generally well tolerated and limited outcome data have determined biologics to be safe for long-term use in moderate to severe plaque psoriasis. However, biologics have been linked to risks of immunosuppression, serious infections and malignancy, both cutaneous and lymphoproliferative.¹¹⁻¹³

Regular blood and liver function tests are required for patients undergoing systemic treatment to monitor the toxicities of these medications, all of which must be avoided in pregnancy.^{4,10}

Table 2: Drugs commonly implicated in oral ulceration		
Rheumatology	NSAI and long-term rheumatoid arthritis therapy	Azathioprine, methotrexate, penicillamine, gold compounds, tiopronin
Cardiology	<ul style="list-style-type: none">Angiotensin-converting-enzyme inhibitors.Angiotensin 2-receptor antagonist	Captopril, enalapril. Losartan, anti-angorous as nicorandil
Psychiatry	Antidepressants	Fluoxetine, lithium
HIV	AIDS therapy	Foscarnet, zalcitabine

Oral ulceration is reported in 14% of patients on long-term, low-dose MTX treatment.¹⁴ The lesions may be caused by a lack of folic acid supplementation or an over-dosage of the MTX drug.¹⁴ Whilst the lesions are aggravated by chronic drug administration, they will disappear three weeks after suspension of the MTX administration. This adverse effect of MTX is mostly dose-dependent and usually occurs due to an accidental over dosage.⁷

Oral side effects are of importance to the patient not only because of the associated pain, but also because it affects the ability to eat. This aggravates the folate deficiency, causes weight loss and leads to a general weakening of health.⁷ Folic acid supplementation can reduce MTX-induced mucosal and gastrointestinal side effects by 79%.⁶

Most of the cases of ulceration induced by methotrexate have been described in patients treated with low-dose (7.5-25mg/wk) instead of a higher dose of methotrexate (100-250mg/m²/wk), probably because hyperproliferative psoriatic plaques are more susceptible to the influence of folate antagonism.^{15,18}

One of the primary toxic effects of methotrexate is myelosuppression. MTX suppressed hematopoiesis has been confirmed to cause anemia, aplastic anemia, leukopenia, pancytopenia, neutropenia, thrombocytopenia, lymphadenopathy, and lymphoproliferative disorders.¹⁶ MTX is thus contraindicated in patients with low hematologic cell counts or pre-existing myelosuppression. Regular monitoring of a complete blood count (CBC) is compulsory and some cases may require temporary discontinuation of the therapy. In addition, folate therapy or leucovorin rescue may prevent or palliate side effects.¹⁷ Low dose methotrexate is increasingly being administered in the control of psoriasis. It is generally an effective and safe medication, with oral ulceration being its most common side effect. Oral ulceration may be due to dosage error or folate deficiency and these problems should be clarified in patients who present with oral ulceration while using methotrexate.¹⁶

Conflict of interest: None declared

References

1. Madinier, I, Berry, N, Chichmanian, RM. Drug-induced oral ulcerations. *Annales de Medecine Interne*. 2000; 151 (4):248-54.
2. Jinbu, Y, Demitsu, T. Oral ulcerations due to drug medications. *Japanese Dental Science Review* 2014; 50(2):40-6.
3. Abdollahi, M, Radfar, M. A review of drug-induced oral reactions. *J Contemp Dent Pract*.2003; 4(1):10-31.
4. Santra, R, Choudhury, S. Acute methotrexate ingestions in adults: A review on ever-rising consumption of methotrexate since 1980s. *International Journal of Health and Allied Sciences* 2015; 4(3):127-134.
5. Richard, EG, Hönigsmann, H. Phototherapy, psoriasis, and the age of biologics. *Photodermatology, Photoimmunology and Photomedicine* 2014; 30(1):3-7.
6. Ortiz, Z, Shea, B, Suarez-Almazor, ME, Moher, D, Wells, GA, Tugwell, P. The efficacy of folic acid and folinic acid in reducing methotrexate gastrointestinal toxicity in rheumatoid arthritis. A meta-analysis of randomized controlled trials. *The Journal of Rheumatology* 1998; 25(1):36-43.
7. Goodman, SM, Cronstein, BN, Bykerk, V.P. Outcomes related to methotrexate dose and route of administration in patients with rheumatoid arthritis: a systematic literature review. *Clinical and Experimental Rheumatology* 2015; 33(2):272-8.
8. Deeming, GMJ, Collingwood, J, Pemberton, MN. Methotrexate and oral ulceration. *British Dental Journal* 2005; 198(2):83-5. <http://www.nature.com/bdj/journal/v198/n2/full/4811972a.html>
9. Schon, MP, Boehncke, WH. Psoriasis. *N Engl J Med*. 2005; 352:1899-1912 PubMed Article
10. Gelfand, JM, Weinstein, R, Porter, SB, Neimann, AL, Berlin, JA, Margolis, DJ. Prevalence and treatment of psoriasis in the United Kingdom: a population-based study. *Archives of Dermatology* 2005; 141(12) :1537-41.
11. <https://en.wikipedia.org/wiki/Psoriasis>
12. Iyyadurai, R, Carey, RAB, Satyendra, S. Low-dose methotrexate-induced acute interstitial pneumonitis: Report of two cases from South India and review of literature. *Journal of Family Medicine and Primary Care* 2016; 5(4):875-8.
13. Kalb, RE, Fiorentino, DF, Lebwohl, MG, Toole, J, Poulin, Y, Cohen, AD, Goyal, K, Fakharzadeh, S, Calabro, S, Chevrier, M, Langholf, W. Risk of serious infection with biologic and systemic treatment of psoriasis: results from the Psoriasis Longitudinal Assessment and Registry (PSOLAR). *JAMA Dermatology* 2015;151(9):961-9.
14. Hanakawa, H, Orita, Y, Sato, Y, Uno, K, Nishizaki, K, Yoshino, T. Large ulceration of the oropharynx induced by methotrexate-associated lymphoproliferative disorders. *Acta Med Okayama*, 2013; 67:265-9.
15. Hsu, MC, Chen, CC. Low-dose methotrexate-induced ulcerated psoriatic plaques: A rare case. *JAAD Case Reports* 2015; 1(5):264-6.
16. Demirkiran, D, Kurt, H, Yüksel, M, Sari, Y. Pancytopenia and mucositis encountered in the early stages of methotrexate treatment. *Eur J Health Sci*. 2016;2:1-3.
17. <https://www.drugs.com/sfx/methotrexate-side-effects.html>.
18. Weidmann, A, Foulkes, AC, Kirkham, N. Methotrexate toxicity during treatment of chronic plaque psoriasis: a case report and review of the literature. *Dermatology and Therapy* 2014;4:145–156. [PubMed]