

# The case of three burials

## - A forensic case book

SADJ September 2020, Vol. 75 No. 8 p445 - p449

L Robinson<sup>1</sup>, LM Sykes<sup>2</sup>, H Bernitz<sup>3</sup>

### CASE REPORT

*The details of this case have been omitted in order to maintain anonymity.*

An elderly male was reported missing from his home by his family. Initially, an inquiry and missing person's docket was opened. On investigation, several suspicious findings, along with other emerging evidence led to the case being changed into one of kidnapping.

Unbeknown to the investigating officers, around the same time a body had been found buried in a shallow grave about 200 kilometers from the missing person's home (*First burial*). The body had been taken to the state mortuary where a post-mortem was performed. At that stage there was no connection made to the missing person's case and after the body remained unclaimed, the corpse was given a pauper's funeral (*Second burial*).

Later, during the police investigation, a suspect admitted to having kidnapped and murdered the victim and led the police to the area where he had buried the body. They found no body present at the burial site, but did discover two chrome cobalt partial dentures (Figures 1-2) and a single maxillary molar tooth (Figure 3).

Ante-mortem dental records (Figure 4) and radiographs of the suspected missing person were obtained from his dentist. These documents, along with the chrome cobalt dentures and molar tooth, were submitted to the

forensic odontology unit at the University of Pretoria for examination and comparative analysis.

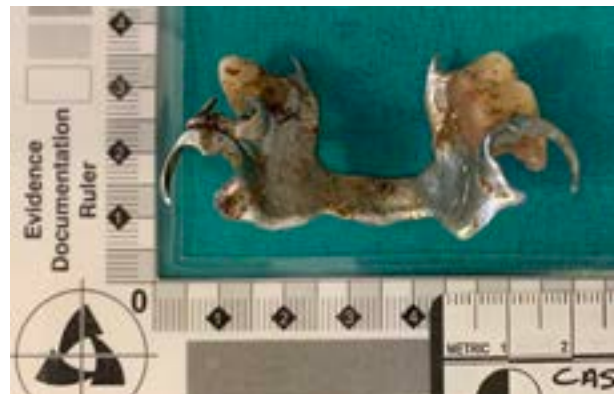

Figure 1. Maxillary chrome cobalt partial denture.

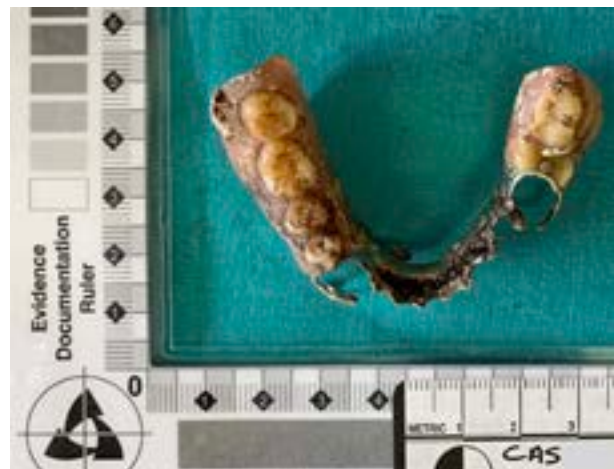

Figure 2. Mandibular chrome cobalt partial denture.

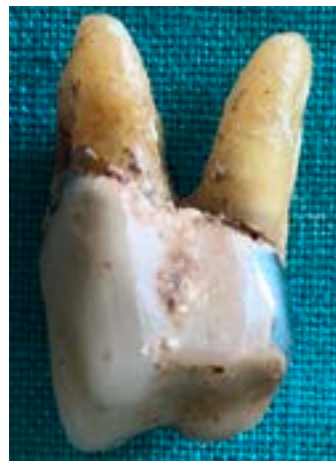

Figure 3. Single maxillary molar tooth.

#### Author affiliations:

1. **Liam Robinson:** BChD, PDD (Maxillofacial Radiology), PDD (Forensic Odontology), Department of Oral Pathology and Oral Biology, School of Dentistry, Faculty of Health Sciences, University of Pretoria, Pretoria, South Africa.  
ORCID Number: 0000-0002-0549-7824
2. **Leanne M Sykes:** BSc, BDS, MDent, Dip Research Ethics (IRENSA), Dip ESMEA (University of Dundee), Dip Odont (Forensic Odontology), Department of Prosthodontics, School of Dentistry, Faculty of Health Sciences, University of Pretoria, Pretoria, South Africa.  
ORCID Number: 000-0002-2002-6238
3. **Herman Bernitz:** BChD, Dip (Odont), MSc, PhD, Department of Oral Pathology and Oral Biology, School of Dentistry, Faculty of Health Sciences, University of Pretoria, Pretoria, South Africa.  
ORCID Number: 0000-0003-1361-1225

#### Corresponding author: Herman Bernitz

Department of Oral Pathology and Oral Biology, University of Pretoria, Pretoria, South Africa.

Email: bernitz@iafrica.com

#### Author contributions:

1. **Liam Robinson:** Primary author - 40%
2. **Leanne M Sykes:** Secondary author - 30%
3. **Herman Bernitz:** Forensic report and advisor - 30%

DENTAL FINDINGS IN PERMANENT TEETH (Notify temporary teeth specifically)			
11		PFM crown	21
12		4 surface tooth-coloured; Endo Rx	22
13		PFM crown; Post & core; Endo Rx	23
14	XLA	XLA	24
15	PFM crown; Post & core; Endo Rx	Missing	25
16	DO tooth-coloured	PFM crown; Post & core; Endo Rx	26
17	Missing	MO tooth-coloured	27
18	Missing	MO tooth-coloured	28
48	Missing	Missing	38
47	Missing	XLA	37
46	XLA	Missing	36
45	Missing	PFM crown; Post & core; Endo Rx	35
44	XLA	DOB tooth-coloured; Endo Rx	34
43	PFM crown; Post & core; Endo Rx		33
42	4 surface tooth-coloured; Endo Rx	B tooth-coloured	32
41	BI tooth-coloured	BI tooth-coloured	31

Figure 4. Reconstructed ante-mortem odontogram.

The forensic evaluation revealed the following points of dental concordance:

- The 3-toothed maxillary chrome cobalt partial denture design corresponded to the missing teeth visible on the supplied antemortem dental radiographs.
- The 6-toothed mandibular chrome cobalt partial denture design corresponded to the missing teeth visible on the supplied antemortem dental radiographs.
- The single maxillary molar tooth had a similar crown pattern and endodontic treatment as the left maxillary first molar tooth in the supplied antemortem radiographs (Figures 5-6).
- The left clasp and occlusal rest of the maxillary chrome cobalt partial denture corresponded to the morphology and rest preparation of the left maxillary first molar tooth (Figures 7-8).

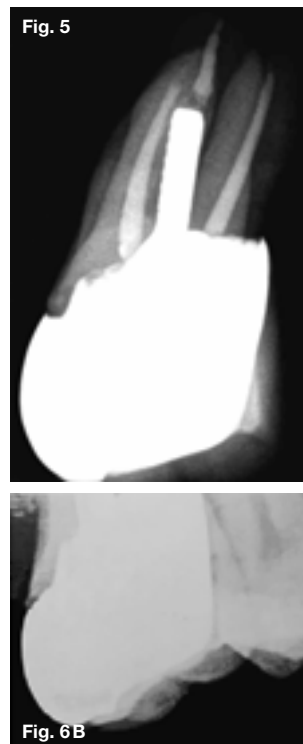
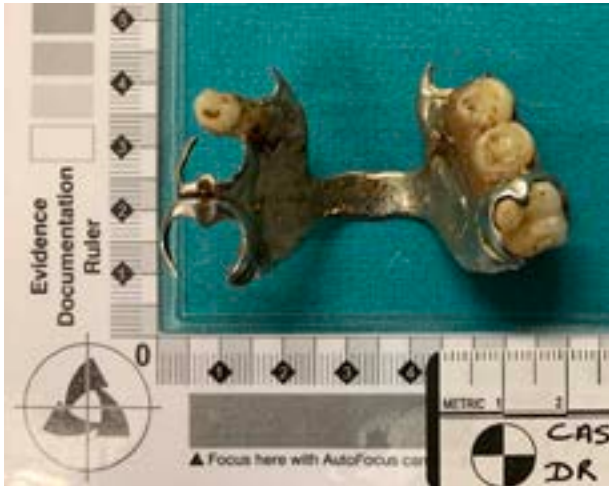

Figure 5. Post-mortem radiograph of the single maxillary molar tooth.

Figure 6. Cropped ante-mortem (A) periapical and (B) bitewing radiographs of the left first maxillary molar tooth.



**Figure 7.** Occlusal view photograph of the left maxillary first molar tooth in position with the maxillary chrome cobalt denture.



**Figure 8.** "Buccal" view photograph of the left maxillary first molar tooth in position with the maxillary chrome cobalt partial denture.

Based on the presence of multiple concordant identifiable dental features and no unexplained discrepancies between the antemortem records and the excavated dentures and maxillary molar tooth, it was concluded with absolute certainty that they all belonged to the missing person in question.

Finally, the kidnapping case was closed, and the pauper's body was once again exhumed for a proper burial by his family (*Third burial*).

## DISCUSSION

The most common role of a forensic odontologist is the identification of deceased individuals.<sup>1-2</sup> Dental identification assumes a primary role when post-mortem changes, traumatic tissue injury or a lack of fingerprint records nullifies the use of visual or fingerprint methods.<sup>1,3</sup>

Teeth not only represent a suitable repository for unique and identifying features, but they also survive most post-

mortem events.<sup>2</sup> The central principle of dental identification is that post-mortem dental remains can be compared with ante-mortem dental records to confirm identity.<sup>1</sup>

In a dentate victim, a forensic odontologist can make use of missing teeth, caries, restorations, partial dentures, onlays, crowns, bridgework and implants.<sup>4</sup> This method relies on dental professionals recording and storing dental notes, clinical photographs, radiographs and study models.<sup>1-2</sup> Individuals with numerous complex dental treatments are often easier to identify than those with little or no restorative work.<sup>2</sup>

Forensic identification based on the assessment of prosthodontic appliances is assuming greater significance, as dental prostheses including crowns, bridge-work, partial or complete dentures, and implants are often made of resilient materials, and can provide additional vital clues for victim identification.<sup>4</sup>

Partial or complete dentures may be discovered in or close to the scene where the body of an unknown individual is found, and can be a useful aid in identification.<sup>5</sup> Other dental prostheses such as removable orthodontic appliances have also been used successfully for identification purposes.<sup>2</sup>

Denture identification is an important component of forensic odontology, since it is often more difficult to identify an edentulous person.<sup>3</sup> In the absence of marked/labelled dentures, dental identification is problematic and may only be established by well-trained examiners via comparison of bone trabeculation patterns recorded in ante-mortem and post-mortem radiographs.<sup>3</sup> Unlabelled dentures recovered from patients can be fitted to casts retained by the treating dentist or laboratory as an identification method.<sup>2,4</sup>

DNA analysis of material collected from dental prostheses is another useful method of identification. A study by Inoue et al. found that even previously worn acrylic resin dental prostheses that had been left at room temperature for as long as 200 days could be used for DNA extraction and analysis for identification purposes.<sup>6</sup>

However, even in the absence of DNA analysis (which is costly and time consuming), a marked/labelled denture can reveal the identity of a deceased person when all other methods fail to do so.<sup>2-3</sup> This emphasises the importance of denture marking/labelling for both forensics and other purposes such as:

- To identify unknown denture wearers in cases involving amnesia or senility, psychiatric cases, homicide, suicide, and victims of natural disasters, air disasters or war.
- In cases of lost and found, the denture can be returned to the owner.
- To provide a rapid and accurate method of identification where fingerprinting is not possible, or where other methods could delay a positive identification.
- In dental laboratories and clinical practices where technicians and dentists can easily identify a marked/labelled denture, thus ensuring the correct denture is delivered to the respective patient.<sup>5,7-8</sup>

In light of these many uses, marking/labelling should not be restricted to acrylic resin dentures, but should also be extended to chrome cobalt partial dentures, orthodontic appliances, maxillo-facial reconstructive prostheses and fixed crowns and bridgework.<sup>1</sup>

Many denture marking/labelling methods exist, including:

- a. **Engraving:** This involves marking the models so that the denture carries the identification spots upon fabrication.
- b. **Scribing:** This involves marking the denture after it has been fabricated with either a bur or any other sharp instrument.
- c. **Writing:** This involves slight disking of the posterior flange of the non-tissue-bearing side of the denture in order to write the identification details.
- d. **Inclusion:** This involves replacement of part of the denture material with a clear acrylic and a medium (metallic, non-metallic labels or microchips) from which identification can be obtained.<sup>1,4-5,8</sup>

More recently, authors have focused their attention on more high-tech methods of denture marking/labelling achieved via the use of radio frequency identification (RFID)-transponders.<sup>9</sup>

Generally, a combination of name and identification number is used inside a denture.<sup>8</sup> Marking/labelling only the initials of an individual into the prosthesis may delay or lead to misidentification, partially if there are many other fatalities. Chrome cobalt dentures and many fixed restorative prostheses have generally never been marked/labelled because of the hardness of the materials, which makes it virtually impossible to etch, scribe or write on them chairside.<sup>5</sup> However, given that they resist melting and distortion at far higher temperatures than acrylic resin, they should also be marked/labelled in some durable and inconspicuous manner.

The American Dental Association (ADA) has described guidelines for denture marking/labelling. (These principles can be extended to all forms of dental/facial prostheses and restorations):

1. The strength of the prosthesis must not be jeopardised.
2. It must be easy, efficient and inexpensive to achieve.
3. The markings must be visible and durable.
4. The markings must withstand humidity and fire.
5. The markings must not interfere with any of the fitting or occlusal surfaces of the prosthesis, and not cause any noticeable discomfort to the patient.
6. The identification marks should be cosmetically acceptable to the wearer.<sup>4,7</sup>

Unfortunately, despite numerous reports in the literature on the benefits of denture marking/labelling, there remains a general sense of apathy and lack of uptake for this in practice. It would appear that this indifference is more on the part of dentists and technicians than the patients.<sup>3</sup> This suspicion was confirmed by studies such as that of Borrman and Rene who found that it was the dental profession, rather than the patient, that was responsible for the non-marking of dentures.<sup>10</sup>

Furthermore, Cunningham and Hoad-Reddick reported that patients were generally in favour of some form of denture marking/labelling,<sup>11</sup> while Richmond and Pretty found the 99% of individuals said they would accept marking/labelling of their dentures.<sup>3</sup>

Currently, only a few countries in the world adhere to a strict denture marking/labelling regimen, with most having different rules or requirements regarding this process. In Sweden for example, it is mandatory for all dentists to offer and motivate their patients to have dentures marked/labelled, but the actual marking/labelling is not enforced.<sup>4</sup> In South Africa, a survey of 23 laboratories and 14 dental surgeries showed that no routine denture marking/labelling takes place.<sup>8</sup> Regardless of legislature, all dentists should inform and motivate their patients about the benefits of denture marking/labelling. Perhaps if this procedure was incorporated into all dental teaching institutions as part of the denture fabrication curriculum for undergraduate students it may gain the importance it deserves.<sup>12</sup>

## CONCLUSION

This case report illustrates the value of dental prostheses and restorations in victim identification. However, not all situations will have the benefit of ante-mortem dental records for comparative purposes, making denture identification all the more important.

In light of the numerous additional benefits this procedure has for patients, the profession and the broader community, and given that modern methods exist to achieve this with durable, undiscernible and relatively inexpensive techniques, it should be considered a mandatory requirement of all dental/facial restorations.

## References

1. Mishra SK, Mahajan H, Sakorikar R, Jain A. Role of prosthodontist in forensic odontology. A literature review. *J Forensic Dent Sci.* 2014; 6(3):154-9.
2. Pretty IA, Sweet D. A look at forensic dentistry -Part 1: The role of teeth in the determination of human identity. *Br Dent J.* 2001; 190(7): 359-66.
3. Richmond R, Pretty IA. Denture marking-patient preference of various methods. *J Forensic Sci.* 2007; 52(6): 1338-42.
4. Bathala LR, Rachuri NK, Rayapati SR, Kondaka S. Prosthodontics an "arsenal" in forensic dentistry. *J Forensic Dent Sci.* 2016; 8(3): 173.
5. Gosavi S, Gosavi S. Forensic odontology: A prosthodontic view. *J Forensic Dent Sci.* 2012; 4(1): 38-41.
6. Inoue M, Hanaoka Y, Minaguchi K. Personal Identification by DNA Analysis of Samples from Dental Prostheses Made of Acrylic Resin. *The Bulletin of Tokyo Dental College.* 2000; 41(4): 175-85.
7. Chalian VA, Sayoc AM, Ghalichebaf M, Schaeffer L. Identification of removable dental prosthesis. *J Prosthet Dent.* 1986; 56(2): 254-6.
8. Bernitz H, Blignaut J. An inclusion technique for marking dentures. *J Forensic Odontostomatol.* 1998; 16(1): 14-6.
9. Richmond R, Pretty IA. The use of radio-frequency identification tags for labeling dentures-scanning properties. *J Forensic Sci.* 2009; 54(3): 664-8.

10. Borrmann HI, DiZinno JA, Wasen J, Rene N. On denture marking. J Forensic Odontostomatol. 1999; 17(1): 20-6.
11. Cunningham M, Hoad-Reddick G. Attitudes to identification of dentures: the patients' perspective. Quintessence Int. 1993; 24(4): 267-70.
12. Richmond R, Pretty IA. The teaching of denture marking methods in dental schools in the United Kingdom and the United States. J Forensic Sci. 2009; 54(6):1407-10.

## Do the CPD questionnaire on page 465

The Continuous Professional Development (CPD) section provides for twenty general questions and five ethics questions. The section provides members with a valuable source of CPD points whilst also achieving the objective of CPD, to assure continuing education. The importance of continuing professional development should not be underestimated, it is a career-long obligation for practicing professionals.



### Online CPD in 6 Easy Steps

- 1 Go to the SADA website [www.sada.co.za](http://www.sada.co.za).
- 2 Log into the 'member only' section with your unique SADA username and password.
- 3 Select the CPD navigation tab.
- 4 Select the questionnaire that you wish to complete.
- 5 Enter your multiple choice answers. Please note that you have two attempts to obtain at least 70%.
- 6 View and print your CPD certificate.