

Demographics of paediatric patients presenting with acute appendicitis: A 5-year retrospective review of hospitals served by the Department of Paediatric Surgery at the University of the Witwatersrand

A Withers, MB BCh; J Loveland, MB BCh, FCS(SA), Cert Paed Surg

Department of Paediatric Surgery, School of Clinical Medicine, Faculty of Health Sciences, University of the Witwatersrand, Johannesburg, South Africa

Corresponding author: A Withers (withers.alt@gmail.com)

Background. There are no recently published data on the incidence and demographics or perforation rates of paediatric patients from our local population presenting with acute appendicitis.

Objective. To show the age and gender distribution of paediatric patients presenting with acute appendicitis within our communities, as well as demonstrating the incidence of perforated acute appendicitis in our paediatric population.

Method. The study is a retrospective record review of all paediatric patients who presented with acute appendicitis to the Department of Paediatric Surgery at both Charlotte Maxeke Johannesburg Academic Hospital (CMJAH), and Chris Hani Baragwanath Academic Hospital (CHBAH) from June 2010 to September 2015. Data collected included all demographic data as well as histology results of patients who underwent appendectomies.

Results. The total numbers of patients included in the study were 544; 234 at CHBAH, and 311 at CMJAH. The male-to-female ratio was 1.58:1. The mean age for presentation at both hospitals combined was 8.76 years. We found that 13.41% of paediatric patients with acute appendicitis in this cohort were under the age of 6 years. A histological review showed that 50.1% of patients in our cohort presented with complicated appendicitis, and we had a negative appendectomy rate of 8.4%. Histological results of patients under the age of 6 years revealed a higher negative appendectomy rate of 11.4%. However, the incidence of complicated appendicitis in this age group was only 45.7%, which is lower than that reported in the literature. Three patients were found to have *Enterobius vermicularis* in the lumen of the appendix, and *Ascaris* ova were identified in one patient. Histology revealed a low-grade mucinous neoplasm in one patient.

Conclusion. Acute appendicitis occurred at a median age of 8.76 years in our study population, with a male-to-female ratio of 1.58:1. We found that acute appendicitis occurred relatively more frequently in our patients under the age of 6 years compared with the incidence of acute appendicitis in this age group published elsewhere. Complicated appendicitis occurred in 50.1% of our patient population, with an increased frequency of perforated appendicitis occurring in our male population. However, complicated appendicitis occurred in only 44.7% of our patients below the age of 6 years, which is in stark contrast to published literature. Helminthic infections were rare associated pathogens in our study, and an unlikely underlying pathogen of acute appendicitis in our population.

S Afr J Child Health 2019;13(2):69-72. DOI:10.7196/SAJCH.2019.v13i2.1557

Acute appendicitis is the most common acute paediatric surgical emergency, with more than 80 000 appendectomies being performed in the USA per annum.^[1] It has a peak incidence between the ages of 12 and 18 years.^[2] The rate of perforated appendicitis in paediatric patients ranges widely between 9% and 76%^[3-5] and occurs more frequently in patients under the age of 5 years owing to a delay in presentation, an under-developed omentum, as well as the fact that the wall of the appendix is relatively thinner in these younger patients.^[6]

There are no recent data on the demographics of paediatric patients presenting with acute appendicitis in a South African population. The aim of the study was therefore to describe the age and gender distribution of paediatric patients presenting with acute appendicitis and to describe the incidence of perforated acute appendicitis in these patients.

Method

This retrospective study was conducted at the Department of Paediatric Surgery, University of the Witwatersrand, and included a review of all patients who presented with acute appendicitis between June 2010 and September 2015. Records of patients from both hospitals serviced by the department, i.e. Chris Hani Baragwanath Academic Hospital (CHBAH) and Charlotte Maxeke Johannesburg

Academic Hospital (CMJAH), were included. The department's database as well as the hospital admissions books were used to identify patients who were admitted with acute appendicitis. These data were cross-referenced with the theatre registry and with submitted histology specimens. All demographic data as well as histology reports were reviewed. Records that were incomplete were excluded from the study.

Permission to conduct the study was obtained from the University of the Witwatersrand Human Research Ethics Committee (Medical) (ref. no. M160374).

Results

A total of 659 records were reviewed. Only 544 patients were included in the study, owing to incomplete records, of whom 311 were from CMJAH and 234 from CHBAH.

Three hundred and thirty-four (61.3%) patients in the study were male. Fig. 1 shows the gender distribution by age, which demonstrates a nearly equal incidence of acute appendicitis in male and female patients below the age of 4 years. A male preponderance of acute appendicitis became evident from the age of 4 years, with a marked increased incidence of acute appendicitis in male patients between the ages of 9 and 13 years, where 68.44% of patients in this age group were male.

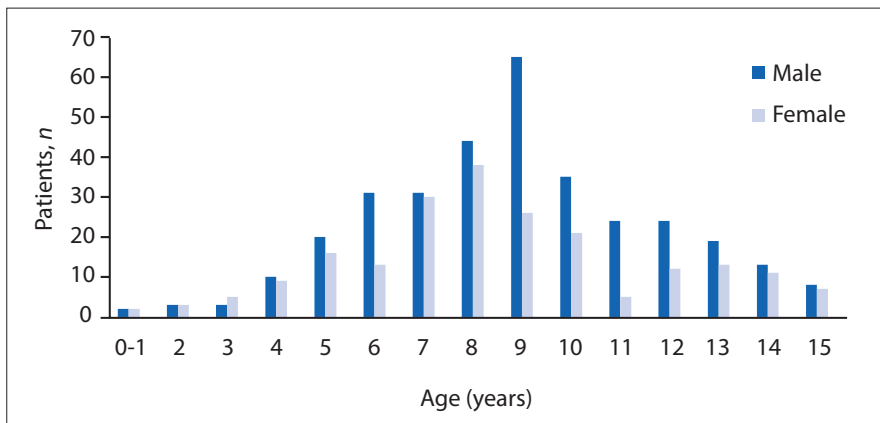


Fig. 1. Breakdown of gender distribution by age.

The mean age of presentation of patients with acute appendicitis at both hospitals combined was 8.8 (range 0.7 - 15.0) years, with 13.4% (73 patients) presenting under the age of 6 years. There was a significant difference in age of presentation between the two hospitals, the mean age of presentation at CHBAH being 7.3 (7 - 10) years, and 9.9 (1.0 - 15.0) years at CMJAH. The difference in mean age of presentation was accounted for by the institutional differences in cut-off ages for paediatric surgery. The cut-off age for paediatric surgery at CMJAH is 16 years, compared with 10 years at CHBAH.

The histology of appendix specimens was reviewed in 501 study patients. They were categorised as uncomplicated if inflamed and not perforated, and as complicated if the appendix was gangrenous or perforated. Uncomplicated appendicitis was present in 40.5% ($n=203$) of our study population (Fig. 2). Histology for each hospital was categorised separately, showing that complicated appendicitis occurred in 55.8% ($n=120$) of patients at CHBAH, compared with 44.4% ($n=127$) of patients at CMJAH. The negative appendectomy rate was 8.4% ($n=42$) in the present study.

Histology results were further examined according to age group and showed that 45.7% ($n=32$) of patients under the age of 6 years had complicated appendicitis, and a histologically normal appendix was found in 11.4% (8 patients) in this age group.

Examination of all histology specimens revealed the presence of *Enterobius vermicularis* in the lumen of the appendix in 3 patients, and *Ascaris* ova in the mucosa of the appendix in 1 patient. One patient had a low-grade mucinous neoplasm.

Discussion

Acute appendicitis has an estimated incidence of 4 per 1 000 school-age children per year in developed countries.^[7,8] Moore *et al.*^[9] from Cape Town, South Africa, reported an overall incidence of 1.8 per 1 000 admissions in the paediatric population. The peak incidence

of acute appendicitis is between the ages of 12 and 18 years.^[2] We found a lower peak incidence of acute appendicitis in our cohort of patients aged between 8 and 10 years, when data from both hospitals were combined. However, this figure was due to the lower age of our patient population, as interrogation of the data per hospital found a peak age between 8 and 10 years at CHBAH and 10 and 12 years at CMJAH owing to the differing cut-off ages for paediatric surgery between the two hospitals. Seventy-three patients (13.4%) with acute appendicitis in our cohort were under the age of 6 years, which is higher than the prevalence of pre-school children presenting with acute appendicitis in the published literature, which is reported to be between 2% and 9%.^[10-12]

There is variation in the reported incidence of acute appendicitis in male and female paediatric patients. Alloo *et al.*^[13] and Ngim *et al.*^[14] reported a 60:40 male-to-female ratio in their study. By comparison, Bansal *et al.*^[1] documented a nearly equal rate of acute appendicitis in their paediatric population of 51% male and 49% female patients. Our study showed a male preponderance of 61.3%, similar to the results by Alloo and Ngim, and also correlated with results from a South African study which showed a male-to-female ratio of 1.74.^[9] Several studies have shown that perforated appendicitis occurs more commonly in males.^[15,16] We examined the perforation rates between male and female patients in our patient population and found that 61.1% of patients with complicated appendicitis were male. This discrepancy became more evident in patients over the age of 10 years, which revealed that 64.1% of patients with complicated appendicitis were male, which is similar to results found by Jaya *et al.*^[15] This discrepancy was not found in patients under the age of 5 years.

Patients presenting with acute appendicitis may present along a spectrum of the disease process ranging from early acute

appendicitis without perforation, to perforated appendicitis with significant intra-abdominal contamination. Complicated appendicitis has been shown to have a negative impact on the morbidity and mortality rate.^[17-19]

Worldwide, the incidence of perforated appendicitis varies,^[3,4] but is noted to be lower in developed countries, with the incidence of perforated appendicitis ranging between 9% and 43%.^[17,20,21] To compare our findings with patients from a similar paediatric environment, a study published by Moore *et al.*^[9] in 1995 showed an incidence of perforated appendicitis of 47% in their patients. We found, similarly, that complicated appendicitis occurred in 50% of our patients. There was, however, a higher incidence of complicated appendicitis at CHBAH of 55.8% (v. 44.4% at CMJAH). This difference in severity of pathology may be accounted for by the fact that there is a larger geographic drainage area served by CHBAH from where patients are referred. It may also be that patients who are referred to CHBAH are referred from more rural areas and may take longer to present or to be referred, compared with patients who are referred to CMJAH, which may contribute to the increased likelihood of presenting with complicated appendicitis. Further investigation, however, is needed to establish the factors that contribute to this difference.

Preschool patients more frequently present with complicated acute appendicitis. This is in part due to the fact that presentation is delayed owing to the inability to communicate symptoms clearly, the wide differential of medical causes of abdominal pain in children, and physiological factors such as a less well-developed omentum and a thinner appendiceal wall.^[6] We examined the incidence of perforated appendicitis in preschool children in our study population and found that 45.7% of patients under the age of 6 years presented with complicated appendicitis. This finding contrasts with published literature, which indicates an incidence of perforated appendicitis of between 60% and 75.7% in this age group.^[1,20,21] The reasons for this difference in our population are not clear. However, the larger proportion of preschool children presenting with acute appendicitis in our population (13.4% compared with 2 - 9% in other studies) may have sensitised healthcare workers to acute appendicitis as a differential diagnosis in younger patients, thereby decreasing delay in further referral and subsequent treatment. Review of histology reports revealed a normal appendix in 8.4% of patients. The percentage of negative appendectomies was higher in patients under the age of 6 years (11.4%), which emphasises the diagnostic difficulty in this age group of patients who present with signs

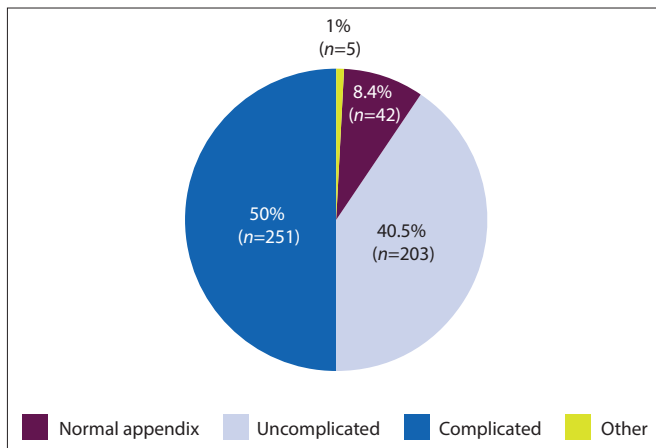


Fig. 2. Breakdown of histology results.

and symptoms that may be suggestive of acute appendicitis, only to have their diagnosis excluded at time of surgery.

Parasitic infestations associated with acute appendicitis are described in between 0.2% and 41.8% of patients.^[22] A worldwide incidence of *E. vermicularis* infestation is reported as between 4% and 28%.^[23-28] *E. vermicularis* is a common pathogen in South Africa, with a prevalence of up to 45% in preschool children in rural South African communities,^[29,30] although there are no current data on the exact prevalence of *E. vermicularis* in our local healthcare region. There is some controversy as to whether *E. vermicularis* is a causative organism in the development of acute appendicitis.^[22,31,32] Only 3 of the patients (0.60%) included in our study were found to have *E. vermicularis* in the lumen of the appendix on histology, suggesting therefore that parasitic infestation is a rare associated pathogen and an unlikely aetiological factor in our patients with acute appendicitis.

Mucinous neoplasms are lesions confined to the appendix or peri-appendiceal tissues without evidence of invasion or disseminated peritoneal disease. These neoplasms typically occur in the 6th decade of life and are only found in 0.2 - 0.7% of adult appendiceal histology specimens.^[33-35] They are exceedingly rare in childhood, with only isolated cases reported in the literature describing mucinous neoplasms in patients under the age of 20 years.^[35-37] Patients may present with right iliac fossa (RIF) pain, a mass or intussusception, or the tumour may be found incidentally.^[37] Complete surgical resection remains the treatment of choice, with a negative proximal margin considered curative for the disease when the neoplasm is limited to the appendix.^[35] One patient included in the present study was found to have a low-grade mucinous neoplasm on histology. The patient was a 7-year-old boy who presented with a 1-day history of RIF pain, and associated vomiting. He underwent a laparoscopic appendectomy, during which an inflamed appendix was noted. Histological examination of the specimen revealed a limited focus of low-grade mucinous neoplasm within the appendix. The resection margins were negative, and appendectomy was therefore curative in this instance.

Study limitations

In this retrospective review, we recognise that the discrepancy in age cut-off between the two hospitals may have a significant impact on the overall demographics of paediatric patients in our local population, especially with regards to the peak age of acute appendicitis. Owing to the nature of the retrospective review, exclusion of patients because of incomplete data may also contribute an element of bias in the study.

Conclusion

This retrospective review demonstrates that acute appendicitis occurs at a median age of 8.8 years in our study population, with

a male preponderance. We found that acute appendicitis occurred relatively more frequently in our patients under the age of 6 years compared with the incidence of acute appendicitis in this age group published elsewhere. We also found that complicated appendicitis occurred in 50.1% of our patient population. However, complicated appendicitis occurred in only 44.7% of our patients below the age of 6 years, which is in stark contrast to published literature. We also confirm that perforated appendicitis occurs more frequently in males. Of interest is the low frequency of helminthic infections associated with acute appendicitis in our population, and that we had 1 patient who was found to have a low-grade mucinous neoplasm on histology.

Acknowledgements. None.

Author contributions. AW: principal investigator, study design, data retrieval and capture, statistical analysis, manuscript writing and final approval. JL: manuscript revision, editing and final approval.

Funding. None.

Conflict of interest. None.

- Bansal S, Banever GT, Karrer FM, Partrick DA. Appendicitis in children less than 5 years old: influence of age on presentation and outcome. *Am J Surg* 2012;204(6):1031-1035. <https://doi.org/10.1016/j.amjsurg.2012.10.003>
- St. Peter S. Appendicitis. In: Holcomb G, Murphy J, eds. *Ashcraft's Pediatric Surgery*, 5th ed. Philadelphia: Saunders, 2010;549-556. <https://doi.org/10.1016/B978-1-4160-6127-4.00043-4>
- Pearl RH, Hale DA, Molloy M, et al. Pediatric appendectomy. *J Ped Surg* 1995;30(2):173-178;178-181.
- Nance ML, Adamson WT, Hedrick HL. Appendicitis in the young child: A continuing diagnostic challenge. *Ped Emerg Care* 2000;16(3):160-162.
- Newman K, Ponsky T, Kittle K, et al. Appendicitis 2000: Variability in practice, outcomes and resource utilization at thirty pediatric hospitals. *J Ped Surg* 2003;38(3):372-379.
- Almaramy HH. Acute appendicitis in young children less than 5 years: Review article. *Ital J Pediatr* 2017;43(1):15. <http://dx.doi.org/10.1186/s13052-017-0335-2>
- Davenport M. ABC of general surgery in children: Acute abdominal pain in children. *BMJ* 1996;312-498. <https://doi.org/10.1136/bmj.312.7029.498>
- Singer JL, Losek JD. Grunting respirations, chest or abdominal pathology? *Ped Emerg Care* 1992;8(6):354-358. <https://doi.org/10.1097/00006565-199212000-00013>
- Moore SW, Schneider J. Acute appendicitis in childhood: Experience in a developing country. *Ped Surg Int* 1995;10(2-3):71-75. <https://doi.org/10.1007/bf00171157>
- Puri P, Boyd E, Guiney EJ, O'Donnell B. Appendix mass in the very young child. *J Ped Surg* 1981;16(1):55-57.
- Rothrock SG, Pagane J. Acute appendicitis in children: Emergency department diagnosis and management. *Ann Emerg Med* 2000;36(1):39-51.
- Andersen S, Paerregaard A, Larsen K. Changes in the epidemiology of acute appendicitis and appendectomy in Danish children 1996-2004. *Eur J Ped Surg* 2009;19(5):286-289. <https://doi.org/10.1055/s-0029-1224199>
- Alloo J, Gerstle T, Shilyansky J, Ein SH. Appendicitis in children less than 3 years of age: A 28-year review. *Ped Surg Int* 2004;19(12):777-779. <https://doi.org/10.1007/s00383-002-0775-6>
- Ngim CF, Quek KF, Dhanoa A, Khoo JJ, Vellusamy M, Ng CS. Pediatric appendicitis in a developing country: What are the clinical predictors and outcome of perforation? *J Trop Ped* 2014;60(6):409-414. <https://doi.org/10.1093/tropej/fmu037>
- Kumar J, Shepherd G, Abubacker M, et al. Trends in incidence of acute appendicitis in children. *Acad J Ped Neonatol [Internet]* 2017;3(5):555682. <https://doi.org/10.19080/AJPN.2017.03.555682>
- Barreto SG, Travers E, Thomas T, et al. Acute perforated appendicitis: An analysis of risk factors to guide surgical decision making. *Ind J Med Sci* 2010;64(2):58-65. <https://doi.org/10.4103/0019-5359.94401>
- Burjonrappa S, Rachel D. Pediatric appendectomy: Optimal surgical timing and risk assessment. *Am Surg* 2014;80(5):496-499. <https://doi.org/10.1097/sla.0000000000001396>
- Yang E, Kahn D, Cook C. Acute appendicitis in South Africa: A systematic review. *S Afr J Surg* 2015;53(3-4):31-38.
- Bonadio W, Pelloquin P, Brazg J, et al. Appendicitis in preschool aged children: Regression analysis of factors associated with perforation outcome. *J Ped Surg* 2015;50(9):1569-1573. <https://doi.org/10.1016/j.jpedsurg.2015.02.050>
- Trent S, Valley M, Brookler K, Haukoos J, Zerzan J. Potential barriers associated with increased prevalence of perforated appendicitis in Colorado's pediatric Medicaid population. *Am J Emerg Med* 2013;31(3):469-472. <https://doi.org/10.1016/j.ajem.2012.09.009>

22. Arca MJ, Gates RL, Groner JI, Hammond S, Caniano DA. Clinical manifestations of appendiceal pinworms in children: An institutional experience and a review of the literature. *Ped Surg Int* 2004;20(5):372-375. <https://doi.org/10.1007/s00383-0041151-5>
23. Waseem M, Simha S. Appendicitis: A rare cause. *J Emerg Med* 2011;41(1):e9-e11. <https://doi.org/10.1016/j.jemermed.2007.11.044>
24. Gatti S, Lopes R, Cevini C, et al. Intestinal parasitic infections in an institution for the mentally retarded. *Ann Trop Med Parasitol* 2000;94(5):453-460.
25. Henley M, Sears JR. Pinworms: A persistent pediatric problem. *MCN* 1985;10(2):111-113.
26. Lee DS, Chung BH, Lee NS, Nam HW, Kim JH. A survey of helminthic infections in the residents of rural areas near Ulaanbaatar, Mongolia. *Korean J Parasitol* 1999;37(3):145-147.
27. Yoon HJ, Choi YJ, Lee SU, Park HY, Huh S, Yang YS. *Enterobius vermicularis* egg positive rate of pre-school children in Chunchon, Korea (1999). *Korean J Parasitol* 2000;38(4):279-281.
28. Ball MT, Hay J. Simultaneous demonstration of eosinophilic granulocytes and mast cells in tissue sections containing helminths. *Ann Trop Med Parasitol* 1990;84(2):195-196.
29. Cranston I, Potgieter N, Mathebula S, Ensink JHJ. Transmission of *Enterobius vermicularis* eggs through hands of school children in rural South Africa. *Acta Tropica* 2015;150:94-96. <https://doi.org/10.1016/j.actatropica.2015.07.001>
30. Mosala TI, Appleton CC. True prevalence of pinworm (*Enterobius vermicularis*) infection among children in Qwa-Qwa, South Africa. *S Afr J Sci* 2003;99:465-466.
31. Zakaria OM. The controversy of parasitic infection in pediatric appendicitis: A retrospective analysis. *Ann Ped Surg* 2012;8(1):15-18. <https://doi.org/10.1097/01.XPS.0000407775.52405.09>
32. Aydin O. Incidental parasitic infestations in surgically removed appendices: A retrospective analysis. *Diag Pathol* 2007;24(2):16. <https://doi.org/10.1186/1746-1596-2-16>
33. Marudanayagam R, Williams GT, Rees BI. Review of the pathological results of 2660 appendectomy specimens. *J Gastroenterol* 2006;41(8):745-749. <https://doi.org/10.1007/s00535-006-1855-5>
34. Smeenk RM, van Velthuysen ML, Verwaal VJ, Zoetmulder FA. Appendiceal neoplasms and pseudomyxoma peritonei: A population based study. *Eur J Surg Oncol* 2008;34(2):196-201. <https://doi.org/10.1016/j.ejso.2007.04.002>
35. Rich BS, Roychoudhury S, Williamson AK, Glick RD. Pediatric mucinous neoplasm of the appendix presenting as a mucocele: A case report and review of the literature. *J Ped Surg Case Reps* 2017;17:11-14. <https://doi.org/10.1016/j.epsc.2016.11.014>
36. Pai R, Beck A, Norton J, Longacre T. Appendiceal mucinous neoplasms: Clinicopathologic study of 116 cases with analysis of risk factors predicting recurrence. *Am J Surg Pathol* 2009;33(10):1425-1439. <https://doi.org/10.1097/PAS.0b013e3181af6067>
37. Blecha MJ, Gupta A, Hoover JD, Madonna MB. Chronic abdominal pain secondary to a mucous cystadenoma of the appendix in a 10-year-old boy. *J Ped Surg* 2005;40(11):1792-1794. <https://doi.org/10.1016/j.jpedsurg.2005.07.065>

Accepted 17 September 2018.