

Cystic lesions of the biliary tree: Proposal for a revised classification system

T. G. MOFOKENG, B.SC., M.B. CH.B.

R. BARRY, M.B. CH.B., M.MED. (SURG.)

Department of Surgery, University of the Free State, and Hepatobiliary Unit, Universitas Hospital, Bloemfontein

O. C. BUCHEL, M.B. CH.B., F.C.P. (S.A.)

Department of Internal Medicine, University of the Free State, and Medical Gastroenterology Unit, Universitas Hospital, Bloemfontein

A biliary cyst is a congenital dilatation of the extrahepatic and/or intrahepatic biliary tract. It occurs in approximately 1:100 000 - 1:150 000 live births, being most common in Japan and among females.¹ Approximately 80% of these cysts are diagnosed before the age of 10, when they classically present with a triad of right upper quadrant pain, a mass and jaundice. In adults, this triad is unusual, and abdominal pain with tenderness is usually the only initial feature.² Alonso-Lej and colleagues first proposed a classification system for bile duct cysts in 1959,³ which was later modified by Todani and colleagues in 1977 (Fig. 1).⁴

Causation

The aetiology of choledochal cysts is still unclear. In 1969, Babbitt postulated that the cysts are caused by an abnormal pancreatico-

biliary duct junction (APBDJ).⁵ An APBDJ is characterised by a long common channel, which is a congenital abnormality defined as a high union of the pancreatic and biliary ducts outside the duodenal wall. It is associated with choledochal cysts in 60 - 90% of cases.²

A long common channel results in free reflux of pancreatic secretions into the biliary tract or bile into the pancreas owing to its course outside the sphincter of Oddi. Pancreaticobiliary reflux results in increased biliary pressure, irritation and inflammation of biliary epithelium and structural damage to the duct wall. This results in cystic degeneration and dilatation of the duct as well as an increased risk of malignant transformation in the biliary epithelium. Biliopancreatic reflux may result in pancreatitis.

Proposed classification

Todani's classification has grouped together separate disease entities with different aetiologies, malignant potential and complications, requiring different surgical interventions.² We propose a revision of the classification system based on the presence or absence of an APBDJ and the associated malignant potential (Table I and Fig. 2).

The current classification of choledochal cysts, according to Todani, describes a heterogeneous group of conditions with separate aetiologies and different malignant potential. We therefore propose a revised classification system for cystic lesions of the biliary tree (types A - D).

Type A biliary cysts include Todani I and IV, which are usually associated with an APBDJ and predispose to biliary malignancy, possibly on the basis of pancreaticobiliary reflux. Type B, a biliary duct diverticulum, represents Todani II, which is not associated with an APBDJ and has a low malignant potential; it is thought to be a gallbladder duplication. Type C, choledochocele, represents Todani III, is also not associated with an APBDJ and has a low malignant potential. It is thought to be a duodenal duplication. Finally, type D, Caroli's disease, represents Todani V, which is a ductal plate anomaly and is associated with congenital hepatic fibrosis. It is not associated with an APBDJ. Therefore, only type A

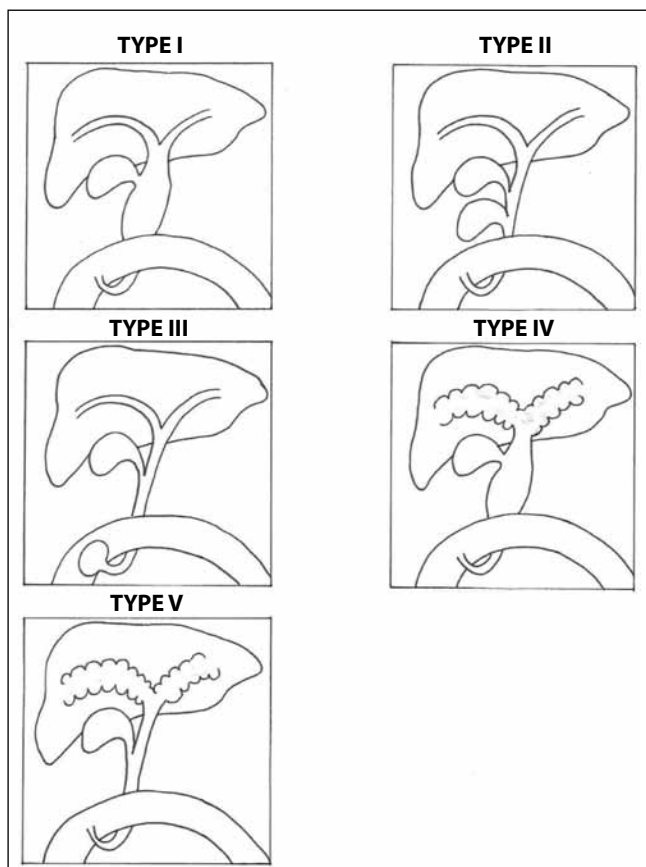


Fig. 1. Todani's classification of choledochal cysts.

TABLE I. REVISED CLASSIFICATION OF CYSTIC LESIONS OF THE BILIARY TREE

Type A: Biliary cysts
 Type B: Bile duct diverticulum
 Type C: Choledochocele
 Type D: Caroli's disease

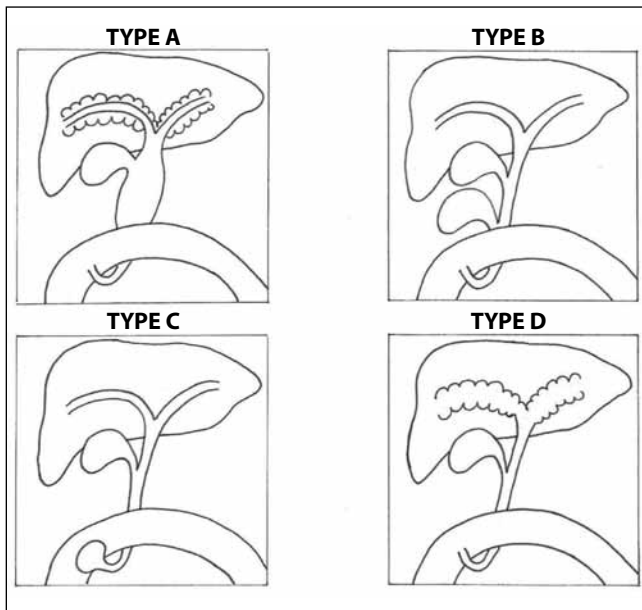


Fig. 2. Revised classification system for cystic lesions of the biliary tree.

cysts are associated with an APBDJ. An APBDJ leads to biliary cyst formation proximally, in the extrahepatic and intrahepatic biliary tract and also predisposes to malignant transformation of the bili-

ary epithelium. Types B and C are possibly congenital duplications, and type D is a ductal plate anomaly with cysts only in the intrahepatic ducts (Caroli's disease). We also propose that the conditions grouped under the Todani classification be called 'cystic lesions of the biliary tree' instead of 'choledochal cysts', as some cysts do not involve the choledochus.

Surgical resection of these cysts is mandatory to minimise the risk of malignancy developing in the future; this does not completely remove the risk of malignancy, however, as the remaining biliary tree is still exposed to pancreaticobiliary reflux. These patients require regular and lifelong follow-up.

REFERENCES

1. Martin RF, Munson JL. Biliary tract surgery. *Surg Clin North Am* 2008;88:1369-1382.
2. Singham J, Yoshida EM, Scudamore CH. Choledochal cysts: classification and pathogenesis. *J Can Chir* 2009;52:437-438.
3. Alonso-Lej F, Rever WB Jr, Pessagno DJ. Congenital choledochal cyst with a report of 2 and analysis of 94 cases. *Int Abstr Surg* 1959;108:1-30.
4. Todani T, Watanabe Y, Narusue M et al. Congenital bile duct cysts: classification, operative procedures, and review of thirty-seven cases including cancer arising from choledochal cyst. *Am J Surg* 1977;13:263-269.
5. Babbitt DP. Congenital choledochal cyst: new etiological concept based on anomalous relationships of the common bile duct and the pancreatic bulb. *Ann Radiol (Paris)* 1969;12:231-240.