

A pelvic “loose” body tumour causing urinary symptoms in a 73-year-old man

T Rosic¹, V Khumalo¹, D G Nethathe²

¹ Department of Surgery, Chris Hani Baragwanath Academic Hospital; University of the Witwatersrand, Johannesburg, South Africa

² Department of Intensive Care, Chris Hani Baragwanath Academic Hospital; University of the Witwatersrand, Johannesburg, South Africa

Corresponding author: DG Nethathe (Gladness.Nethathe@wits.ac.za)

Giant peritoneal loose bodies are very rare. Only a few cases have been reported in the literature. The mechanism of their formation is currently unknown. However, the hypothesis is that a detached appendix epiploicae becomes calcified over time in the abdominal cavity. We present a case of a 73-year-old man who presented with urinary symptoms. Computed tomography (CT) of the abdomen and pelvis revealed a well circumscribed mass in the pelvis. A firm egg-shaped mass was excised laparoscopically. Histology confirmed a giant loose peritoneal body.

S Afr J Surg 2016;54(2)

A 73-year-old man with known diverticular disease presented to the surgical unit complaining of a two-year history of bladder fullness, difficult micturition and tenesmus. The investigation did not show a urinary tract or rectal cause for his symptoms. CT of the abdomen and pelvis was performed, which showed a pelvic soft tissue mass with central calcification (Figure 1). The diagnosis of the mass was unclear, and a laparoscopy-assisted biopsy of the mass was planned. At laparoscopy, a yellow, well circumscribed, oval mass resembling an egg, located below the bladder and anterior to the rectum, was identified. It had no direct blood supply, but was adherent to the bladder wall. The mass was laparoscopically dissected off the bladder, and removed through a 5cm Pfannenstiel incision. Macroscopically, the external surface was smooth, with a vaguely laminated appearance (Figure 2). The bisected specimen dimensions were 66mm x 56mm x 40mm. The specimen weighed 130g. The cut surface was of a firm consistency and cream in colour, with central calcification (Figure 2). Microscopically, the mass consisted of an outside layer of homogenous fibrous tissue. There was dystrophic calcification and fat necrosis towards the centre. There was no evidence of neoplasia, viral cytopathy, granulomata or vasoformative proliferation. These are all features compatible with an appendix epiploica, displaying degrees of fibrosis, fat necrosis and calcification. The patient made a successful recovery and was discharged two days postoperatively. He is currently asymptomatic.

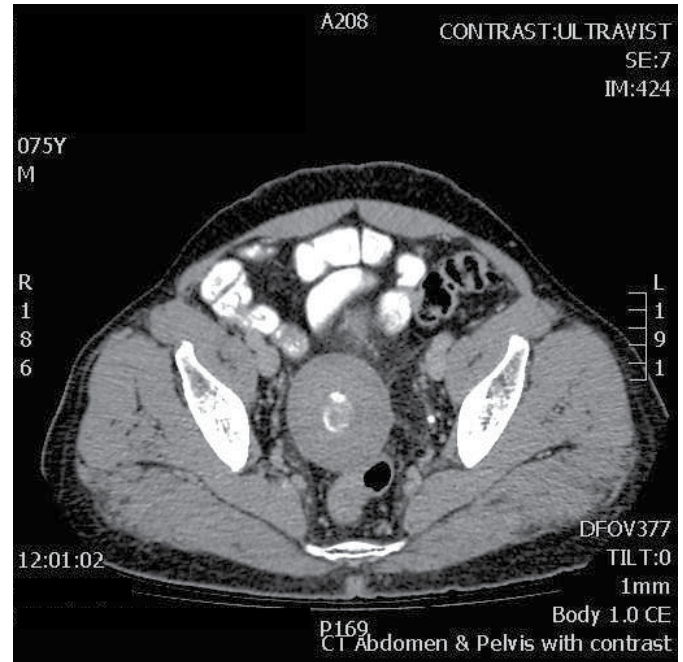


Figure 1: A well circumscribed pelvic soft tissue mass, with central calcification abutting the rectum

The bisected specimen dimensions were 66mm x 56mm x 40mm. The cut surface was of a firm consistency and cream in colour, with an area of central calcification

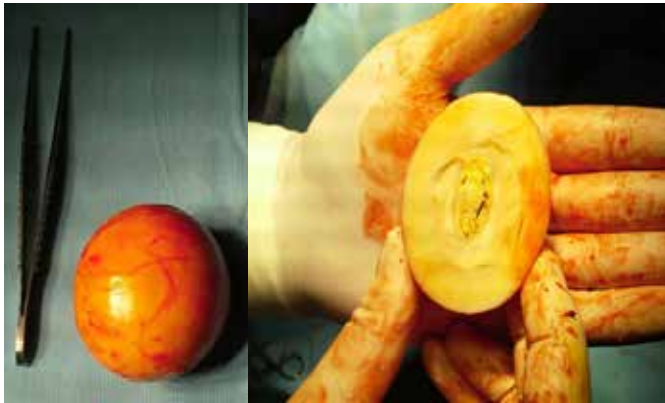

Figure 2: The complete specimen shows a well circumscribed encapsulated yellow mass

Discussion

Giant loose peritoneal bodies or “peritoneal mice” are very rare, often presenting as incidental findings during surgery or post mortem.² Only a few case reports have been published regarding this entity. They are thought to arise from appendices epiploicae, which are fat-containing structures present along the colon. They are covered by serosa and are most abundant in the transverse colon. The average person has 50–100 of them. The first report of a free-lying appendix epiploicae was by Harrigan in 1917. However, the theory of the formation of loose peritoneal bodies was purported by Virchow much earlier in 1863.³ Their formation is most likely due to saponification and calcification of a detached epiploica. They are commonly described as being small, pea sized and loose bodies, owing to their mobile nature, unlike in our patient. None have been described as being fixed pelvic masses. They can attach to the omentum and receive blood

supply from it, a process described as parasitisation.¹ In our case, there was no such parasitisation.

Peritoneal loose bodies are usually asymptomatic and present as incidental findings during surgery or post mortem.² They have been known to be symptomatic, as in our case, often presenting as a cause of a mobile abdominal mass or with pressure effects, leading to pain and compression. Their position in the pelvis is not surprising because of the effects of gravity.⁴

The differential diagnosis for such a mass ranges from benign lesions, such as urinary stones, to dystrophic calcification within malignant lesions, as well as infectious processes, such as tuberculosis. As a result, symptomatic lesions should be removed and malignancy excluded. The prognosis after removal is good.

Conclusion

Giant peritoneal bodies are rare, and are usually an incidental finding. They are usually described as loose bodies, but as our case demonstrated, they can present as fixed masses. If symptomatic, they should be removed and malignancy excluded.

REFERENCES

1. Sewkani A, Jain A, Maudar K, Varshney S. “Boiled egg” in the peritoneal cavity: a giant peritoneal loose body in a 64-year-old man: a case report. *J Med Case Rep.* 2011;7(5):297.
2. Takabe K, Greenberg JI, Blair SL. Giant peritoneal loose bodies. *J Gastrointest Surg.* 2006;10(3):465–468.
3. Harrigan AH. Torsion and inflammation of the appendix epiploicae. *Ann Surg.* 1917;66(4):467–478.
4. Gayer G, Petrovitch I. CT diagnosis of a large peritoneal loose body: a case report and review of the literature. *Br J Radiol.* 2011;84(1000):e83–e85.