
CASE REPORT AND REVIEW OF THE LITERATURE

High-pressure injection injury of the thumb

Neal Goldstein MBBCh

Orthopaedic Registrar, University of the Witwatersrand

Grant Biddulph MBBCh, FC(Orth)(SA)

Orthopaedic Consultant, Hands Unit, Chris Hani Baragwanath Academic Hospital

Prof M Lukhele MBChB, FCS(Orth)SA, MMed(Orth)

Head of Department, Division of Orthopaedics, University of the Witwatersrand

Reprint requests:

Dr N Goldstein

21 Oakwood Estate

51 Oaklands Road

Orchards

2192

Cell: 084 518 9414

Email: goldstein.neal@gmail.com

Abstract

High-pressure injection injuries of the hand are relatively rare but potentially devastating injuries. We highlight a clinical case that presented to the Chris Hani Baragwanath Academic Hospital Hand Unit. The pathophysiology of this phenomenon, as well as the risk factors associated with a poor prognosis, is discussed. Management strategies are explored after a review of the literature.

This case demonstrates the results from delays in early surgical management and the lack of education about high-pressure injection injuries amongst employers, employees and primary health care physicians.

Key words: High-pressure injection, hand, paint gun injury, occupational injury

Introduction

High pressure injection injuries of the hand are important, often underestimated injuries. The injury refers to the injection of various substances under high pressure usually in the domain of accidental occupational exposure. Awareness of the grave complications associated with this seemingly innocuous injury is important.

We present a patient who presented to Chris Hani Baragwanath Academic Hospital (CHBAH) with a high pressure injection injury to his non-dominant thumb.

Case report

A 27-year-old, right-hand dominant male, presented to the emergency department at CHBAH. He complained of a painful left thumb and reported an injury that had occurred ten days previously.

Awareness of the grave complications associated with high pressure injection injuries of the hand is important

The patient was spraying road markings when the pipe connecting the paint dispenser to the gun became tangled. In his attempt at correcting this, the pipe burst and instinctively he placed his left thumb over the pipe to try and prevent the paint from escaping. He sustained a high-pressure injection injury to his left thumb. He noticed a small puncture wound on the pulp of the thumb and attempted to squeeze it. White paint came out of the small puncture site, and the patient was relieved when this was replaced by blood. He was only given oral analgesics and sent home.

The gravity of the condition was also not appreciated at the peripheral clinic he attended in Soweto eight days later. Only antibiotics and analgesics were dispensed, for what was believed to be a trivial injury.

On the eleventh day post injury the clinic referred him to CHBAH. On arrival, the thumb was exquisitely painful and skin changes were evident. There was necrosis of the distal portion and white paint could be expressed from the pulp space (Figure 1). X-rays showed radio-opaque paint in the area of the distal phalanx, and it was noted that the paint had tracked down the flexor sheath to the region of the metacarpophalangeal joint (Figure 2).

The grave prognosis was explained to the patient and the risks of formal amputation were discussed. However, at this stage the patient was reluctant. Initial debridement was performed under regional anaesthesia (coracoid block). The necrotic pulp was excised. The digital nerves and flexor pollicis longus tendon were encased and destroyed by the paint up to the level of the MCPJ. Debridement was difficult as the paint was fixed to the tissue.

At a second theatre sitting, two days later, the patient agreed to amputation. The distal end of the thumb was not viable, and a terminalisation was performed through the interphalangeal joint. The patient was discharged with oral antibiotics and analgesia.

The patient was rehabilitated and returned to work six weeks after the initial injury with a well-healed amputation stump (Figure 3).

Discussion

Perhaps the first mention of this type of injury was by Rees in 1937 when he reported a mechanic who suffered an injection injury of diesel into his right middle finger.¹ Since then over 400 cases have been reported in the literature, but to date no randomised controlled trials, comparing treatment modalities, have been performed.² It is a relatively rare presentation to the hand surgeon and has been estimated to be approximately 1 in 600 cases that present to a busy hand unit.³ Neal and Burke⁴ reported only 11 cases over a five-year period, and 25 cases over a 15-year period was reported by Pinto *et al.*⁵

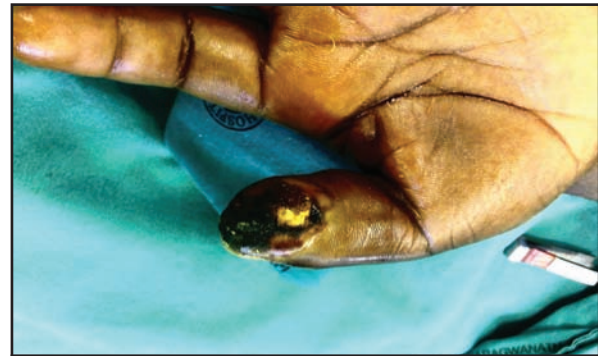


Figure 1. Necrotic pulp

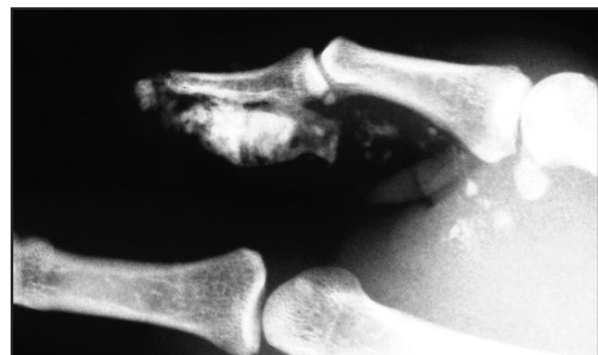

Figure 2. X-ray: radio-opaque paint in region of distal phalanx and tracking down flexor sheath of thumb

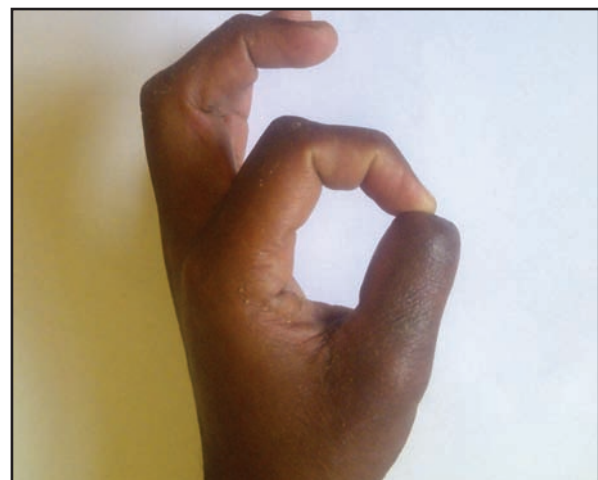

Figure 3. Final post-operative result

History and clinical presentation

The mechanism of injury, the nature of the substance injected and the time of injury are all important risk factors. It is often the non-dominant hand that is affected (78%) and the index finger is the most common site. Males are predominantly affected with a mean age of 34.7 years.²

The patient and primary health care workers often downplay the severity of this injury as all that is evident is a small puncture wound. Over time the affected part becomes swollen and tender and exquisitely painful. If there is significant pressure within the digit it may become cold and numb and even be considered as a 'digital compartment syndrome'.⁶

Pathophysiology

The pathophysiology of this condition is multifactorial: a mechanical pressure effect from the injected substance, toxic nature of the substance and the resultant vessel thrombosis or vasospasm.² Paint and paint thinners have a significant toxic effect. Gelberman *et al*⁷ found that injection of paint resulted in a poorer prognosis than grease, and Kaufman's series reported that paint resulted in the greatest percentage of amputations.⁸

The site of injury is also important. Finger tips are especially at risk because of the tight fascial planes. Injections to the thumb and palm are associated with fewer amputations.

A foreign-body reaction occurs if the substance is not removed, leading to fibrosis, oleomas and draining sinuses.⁹ Once necrosis has set in, secondary bacterial infection is possible.

Numerous other substances have been implicated in high-pressure injection injuries of the hand, including: air, animal vaccines, diesel, grease, hydraulic fluid, oil, water, molten metal and others.

The pressure at which the substance is injected may also play a role. Schoo *et al* in 1980 stated that injection pressures greater than 7 000 psi invariably led to amputation.¹⁰ However two cases have since been identified in the literature in which amputation did not occur. The meta-analysis by Hogan *et al* did identify a 19% amputation rate with injection pressure less than 1 000 psi, and 43% amputation rate with pressures greater than 1 000 psi.² A pressure of only 100 psi can break the skin.¹¹ At much higher pressures, the nozzle of the spray gun does not even need to be in contact with the skin for an injection injury to occur.

Investigations

Plain radiographs may demonstrate evidence of the offending substance. Lead-based paint often is radio-opaque. Evidence of lucent areas on the radiograph may point to radiolucent substances that have displaced normal tissues or may even be injected air. It is possible that the injected substance may travel along fascial planes or in flexor sheaths.

Management (Table I)

Prevention

This injury was originally thought to occur in mainly inexperienced workers (less than six months in employment).⁸ However, Hart *et al* showed no clear correlation with injury and experience. They concluded that manufacturing and design changes would have a greater effect than education alone.¹²

Awareness

Employers, employees, occupational health care workers and primary care physicians should refer to an appropriate specialist centre as soon as possible.

The injured site should **not** be cooled, as this may encourage fixing of the substance to the tissues or promote vasoconstriction. Ring blocks in casualty should be avoided as this may further compromise the delicate vasculature.

Pharmaceutical adjuncts

Tetanus toxoid should be routinely administered.

Broad spectrum intravenous antibiotic coverage is considered helpful especially if secondary infection is a risk.

The use of steroids is controversial – the initial hypothesis being that they would dampen the inflammatory response often responsible for much of the secondary damage. While steroids have been advocated by some authors,^{10,13} they have not shown a clear benefit in decreasing amputation rates.² As no randomised controlled trials exist, the jury is still out.

Table I

Do	Don't	Maybe	Risks for amputation
injury prevention	cooling digit	corticosteroids	delay in debridement
early recognition	ring blocks	radical debridement and immediate coverage	site of injection: fingertip vs palm
early debridement	exsanguination of limb	observation alone for low risk substances	pressure of injection
early rehabilitation	organic solvents at debridement	early formal amputation	type of substance injected
regional anaesthesia			
broad spectrum antibiotics			

Observation

Patients with high-pressure injections of air, water or a small amount of animal vaccine can be observed, as chemically these substances may not cause significant damage.^{2,14,15}

However, careful observation documenting vascular and neurological status is important, as they may progress to a more serious injury.

Debridement

Early aggressive debridement should take place as early as possible in the case of paint, organic solvents, diesel or oil. The benefit of early wide surgical debridement is that it relieves the compartment pressure, attenuates the inflammatory response and reduces bacterial counts.²

Beguín *et al* reported on the beneficial effect that regional anaesthesia of the stellate ganglion and brachial plexus might produce in diminishing sympathetic tone and encouraging vasodilatation in the affected digit.¹⁶

O'Sullivan *et al*⁷ and Pinto *et al*⁵ recommend an 'open wound' technique comprising surgical debridement followed by drainage, open packing, dressing changes and repeat debridement at 24–72 hours. Delayed closure or closure by secondary intention can occur once the wounds have settled.

Del Piñal *et al* presented a case of high-pressure tar and paint thinner injection into a patient's thumb. They postulated that the 'open' method of Pinto would lead to further tissue damage by the toxic effect of the retained agent, as well as secondary desiccation of anatomical structures.⁶ They recommended radical debridement followed by immediate coverage. In that particular case they used a free hallux hemi-pulp transfer.

Irrigation with organic solvents leads to additional tissue damage and is not recommended. Gentle lavage with ringers lactate or saline solution is preferred. The use of an Esmarch bandage to exsanguinate the limb should be avoided, as it may potentiate spread of the substance.

Amputation

Stark in 1967¹⁸ and Kaufman in 1968⁸ believed that the prognosis from paint injection injuries was so poor that initial amputation should be performed. Lower morbidity and earlier return to work can be considered a benefit of early amputation.

The meta-analysis by Hogan *et al*¹ revealed that amputation rates were 40% if debridement occurred within 6 hours, 57% if delayed beyond 6 hours, and 88% if delayed longer than one week. As mentioned previously, the type of material injected significantly affects the amputation rate. Oil-based paints carry the highest risk (58%).

Rehabilitation

Some authors recommend early active and passive rehabilitation, even before the wounds have fully healed.^{4,5} Swelling and loss of function secondary to fibrosis can significantly alter the final outcome.

Conclusion

High-pressure injection injuries of the hand can be devastating. Awareness and injury prevention are vital. Future recommendations include increased vigilance in the workplace and primary care settings to recognise this clinical entity early.

References

1. Rees CE. Penetration of tissue by fuel oil under high pressure from diesel engine. *JAMA* 1937;109:866-67.
2. Hogan CJ, Ruland RT. High-pressure injection injuries to the upper extremity: a review of the literature. Review. *J Orthop Trauma* 2006 Jul;20(7):503-11.
3. Verhoeven N, Hierner R. High-pressure injection injury of the hand: an often underestimated trauma: case report with study of the literature. *Strat Traum Limb Recon* 2008;3:27-33.
4. Neal NC, Burke FD. High-pressure injection injuries. *Injury* 1991;22(6):467-70.
5. Pinto MR, Turkula-Pinto LD, Cooney WP, *et al*. High pressure injection injuries of the hand: review of 25 patients managed by open wound technique. *J Hand Surg A* 1993;18A:125-30.
6. del Piñal F, Herrero F, Jado E, Fuente M. Acute thumb ischemia secondary to high-pressure injection injury: salvage by emergency decompression, radical debridement, and free hallux hemipulp transfer. *J Trauma* 2001;50:571-74.
7. Gelberman RH, Posch JL, Jurist JM. High-pressure injection injuries of the hand. *J Bone Joint Surg Am* 1975 Oct;57(7):935-37.
8. Kaufman HD. The clinicopathological correlation of high-pressure injection injuries. *Br J Surg* 1968;55:214-18.
9. Harter TM, Harter KC. High-pressure injection injuries. *Hand Clin* 1986;2:547-52.
10. Schoo MJ, Scott FA, Boswick JA. High-pressure injection injuries of the hand. *J Trauma* 1980;20:229-38.
11. Scott AR. Occupational high pressure injection injuries: pathogenesis and prevention. *J Soc Occup Med* 1983;33:56-59.
12. Hart RG, Smith GD, Haq A. Prevention of high-pressure injection injuries to the hand. *Am J Emerg Med* 2006 Jan;24(1):73-76.
13. Bottoms, RWA. A case of high pressure hydraulic tool injury to the hand. Its treatment aided by dexamethasone and a plea for further trial of this substance. *Med J Australia*, 1962;2:591-92.
14. Woodward KN. Veterinary pharmacovigilance. Part 4. Adverse reactions in humans to veterinary medicinal products. *J Vet Pharmacol Therap* 2005;28:185-201.
15. Subramaniam RM, Clearwater GM. High pressure water injection injury: emergency presentation and management. *Emerg Med* 2002;14:324-27.
16. Beguín JM, Poilvache G, Van Meerbeeck J, de Coninck A. Hand injuries caused by high pressure injection. Contribution of loco-regional anaesthesia. *Ann Chir Main* 1985;4(1):37-42.
17. O'Sullivan ST, Beausang E, O'Donoghue JM, O'Shaughnessy M, O'Connor TPF. The importance of open wound management in high-pressure injection injuries of the upper limb. *J Hand Surg [Br]* 1997;22:542-43.
18. Stark HH, Ashworth CR, Boyles JN. Paint gun injuries of the hand. *JBJS-A*. 1967;49A:637-47.