

---

# REVIEW ARTICLE

---

## Anatomy of the posterior cruciate ligament

JJ Marais MBChB, MMed(Orth)(Stel)  
Durbanville Medi-Clinic

**Reprint requests:**

Dr JJ Marais  
Durbanville Medi-Clinic  
PO Box 3484  
7551 Durbanville  
Tel: (021) 975-2686  
Fax: (021) 975-2688  
Email: kmarais@kingsley.co.za

### Abstract

The indication for surgery in isolated posterior cruciate ligament (PCL) rupture remains unclear. Although conservative treatment seems to be compatible with good functional outcome in the short and medium term, surgery seems to improve the subjective outcome in symptomatic patients.<sup>1</sup>

Because as a principle 'form follows function' understanding the anatomy is both important in clinical examination and the subsequent decision to treat the PCL rupture conservatively or surgically. For the purpose of this paper I did a literature review as well as a fresh cadaveric dissection in order to search for the relevant biomechanical and anatomical factors of importance when embarking on surgical reconstruction. I hope that it will help surgeons to simplify the surgical anatomy. Better knowledge of the anatomy will improve the quality of reconstruction as in the case of anterior cruciate ligament repairs.

### Biomechanics

The posterior cruciate ligament is the primary constraint to posterior translation of the tibia.<sup>2,4</sup> This function becomes progressively more important towards deeper flexion. During sectioning of the PCL the posterior shift of the tibia was statistically significant from 20 to 90 degrees of flexion with a maximum of  $10 \pm 3$  mm at 90 degrees of flexion when a posterior directed force was applied.<sup>2</sup> Posterior displacement in excess of 10 mm is very suggestive of a more complex injury, e.g. associated posterolateral ligamentous structures.<sup>5</sup>

The posterior cruciate ligament also acts as a secondary constraint in conjunction with the posterolateral corner to prevent external and varus rotation. The primary constraint to external rotation seems to be the posterolateral corner (PLC) and more specifically the popliteus tendon and popliteo-fibular ligament. The popliteus and

popliteo-fibular ligament have similar *in situ* forces under external rotation at any flexion angle increasing with increased flexion before decreasing slightly after 90 degrees.<sup>6,7</sup> An isolated rupture of the PCL increases external and varus rotation by only a few degrees and may not be that significant. Combined PCL and posterolateral corner (PLC) ruptures increase the external rotation by as much as 14 degrees and varus rotation by as much as 7 degrees. Substantial increase in rotation only occurs when two or more of the structures of the PLC (lateral collateral ligament, popliteus complex or posterolateral capsule) are sectioned.<sup>2,5,8</sup>

The posterior cruciate ligament helps to facilitate femoral rollback of the femur during flexion.<sup>2,9</sup> Kumagai *et al* and Davis *et al* found that in the intact knee the femur translates posteriorly with respect to the tibia on average 15.4 mm over the entire flexion range.

Transection of the PCL decreased femoral rollback to a net average of 6.2 mm.

With PCL deficiency increased posterior translation of the tibia shifts the femoral contact point on the tibia anteriorly (*Figure 1*). This will unload the posterior horn of the medial meniscus and increase wear on the medial articular surface. The decrease in contact area as well as altered joint congruency results in increased contact pressure on the anterior portion of the medial tibial plateau with a negative effect on articular cartilage wear. The patellar flexion angle increases significantly throughout flexion after PCL resection with the maximum effect at 50 degrees of flexion (*Figure 2*). The increased patellar flexion angle is most likely due to posterior translation of the tibia. Posterior translation reorientates the patella tendon more posteriorly and thereby increases the patellofemoral joint reaction force on the inferior pole of the patella. The combination of an increased patella flexion angle and an increased posteriorly directed force is most likely a reason for increased patellofemoral pressure and degeneration of patellofemoral cartilage.<sup>2,10</sup>

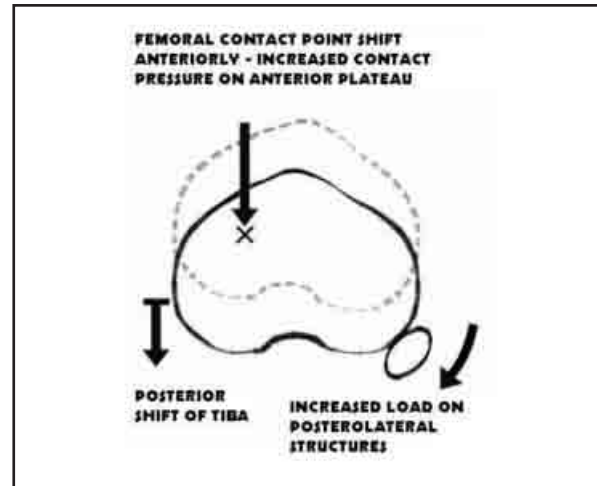
## Anatomy

### Posterior cruciate ligament bundles

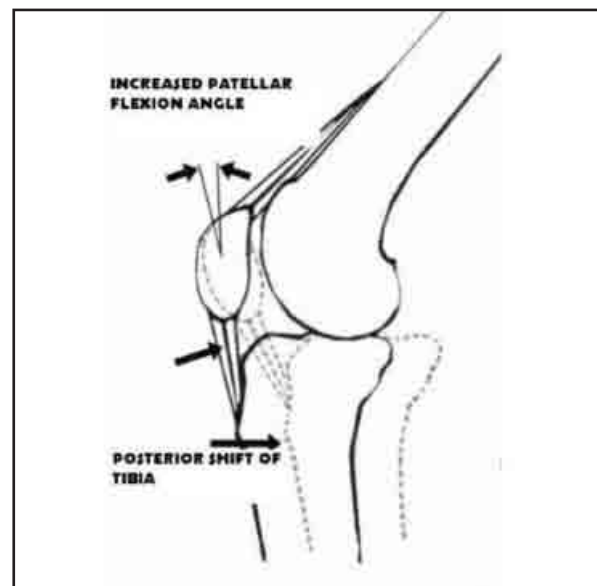
Traditionally the PCL has been divided into the anterolateral bundle comprising about 85% of the bulk, and the posteromedial bundle comprising about 15% of the bulk of the ligament (*Figure 3*). It is thought that the anterolateral bundle is lax in extension and tight in flexion while the posteromedial bundle is tight in extension<sup>11</sup> (*Figures 4 and 5*). The average length at 90 degrees of flexion is  $38 \pm 2$  mm. Anteroposterior diameter measured at the mid-section of the ligament averaged  $5 \pm 0.5$  mm and the mediolateral diameter averaged  $14 \pm 0.8$  mm.<sup>12</sup> The cross-sectional area of the PCL is about 120 to 150% of the ACL. The mean ultimate load for the anterolateral component was  $1\ 120 \pm 362$  N whereas the means of the posteromedial component was  $419 \pm 128$  N.<sup>11</sup> Thus, the ultimate load to failure and linear stiffness of the anterolateral component was found to be two to three times higher than that of the posteromedial component.

### Femoral attachment

The femoral attachment is semicircular or oval and is 300 to 500 per cent larger than the mid-substance diameter.<sup>11</sup> The AP length is  $22 \pm 3$  mm with no clear separation seen between the bundles at the insertion site.<sup>13</sup> The anterolateral bundle attaches mostly to the roof of the intercondylar notch of the femur while the posteromedial bundle attaches mostly to the medial sidewall of the notch onto the medial femoral condyle (*Figure 6*). Using the face of a clock the anterolateral bundle of the left knee attaches from 09h00 to 12h00 with the centre of attachment being  $10\text{h}20 \pm 00\text{h}30$ . The centre of attachment is  $7 \pm 2$  mm from the edge of the articular cartilage. The posteromedial bundle attaches from 07h30 to 10h30 with the centre being  $08\text{h}30 \pm 0\text{h}30$ .



**Figure 1: The tibiofemoral contact point shifts anteriorly in the PCL deficient knee**



**Figure 2: The effect of PCL rupture on patellofemoral load**

The centre of the posteromedial bundle is  $10 \pm 3$  mm from the edge of the articular cartilage.<sup>13,14</sup> The bony topography of the femoral attachment shows a medial intercondylar ridge. The attachment of the PCL lies distal to this medial intercondylar ridge. (*Figure 7*) In a number of cases a secondary ridge, the so-called medial bifurcate ridge, separates the two bundles.<sup>14</sup> The distance between the centres of the anterolateral and the posteromedial bundle is  $11 \pm 1.18$  mm.

**The patellar flexion angle increases significantly throughout flexion after PCL resection**

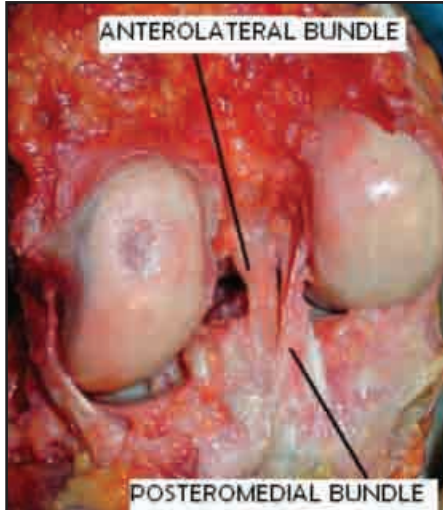


Figure 3: The anterolateral and posteromedial bundles of the PCL

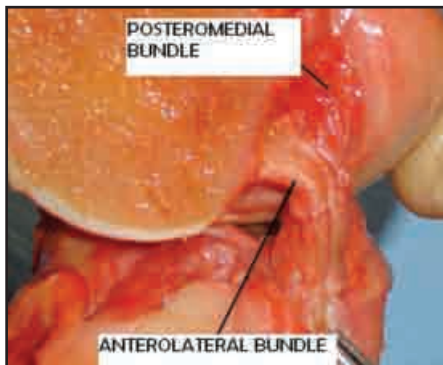


Figure 4: The anterolateral bundle is lax and posteromedial bundle tight in extension

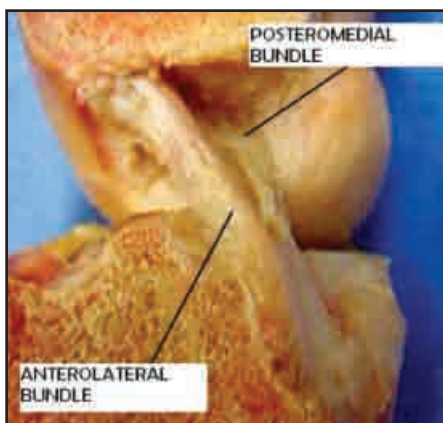


Figure 5: The anterolateral bundle is tight in extension and posteromedial bundle lax in flexion

**Tibial attachment of the PCL**

The tibial attachment is on the sloping central depression posteriorly between the medial and lateral condyles of the tibial plateau (Figure 8 and 9). This attachment is trapezoidal in shape. It is level or below the articular surface and posteriorly it slopes down to a small transverse ridge on the posterior surface of the tibia.<sup>13,15</sup> There is a non-distinct separation between the two bundles. The anterolateral bundle covers the flat intercondylar surface area from the posterior edge of the medial meniscus root to  $\pm 2$  mm from the posterior edge of the tibial plateau. The posteromedial bundle covers the posterior surface of the tibia down to the oblique transverse ridge. The medio-lateral position of insertion of the bundles can be described as a percentage of the medio-lateral width of the tibial plateau from the medial tibial edge. The anterolateral bundle is inserted  $48\% \pm 4\%$  of the medio-lateral width of the tibial plateau from the medial tibial edge. The same measurement for the posteromedial bundle was  $48\% \pm 5\%$ . The posterior fibres of the posteromedial bundle blend with the fibres of the tibial periosteum. The total AP length of the tibial insertion is 14 to 18 mm. Radiographically the PCL insertion covers the posterior half of the PCL fossa. The centre of the insertion of the PCL is in fact the centre of the posterior half of the PCL fossa and approximately 7 mm anterior to the posterior cortex of the tibia when viewed on a proper lateral X-ray<sup>16</sup> (Figure 10). Anteroposterior length of the insertion sites of the AL bundle and PM bundles are  $8 \pm 2$  mm and  $6 \pm 1$  mm respectively, while the width of these insertion sites are  $9 \pm 2$  mm and  $10 \pm 2$  mm respectively.<sup>13</sup>

**Microsurgical dissection**

Under microsurgical dissection of the PCL, Makris *et al* suggested that the bundle structure appears to be more complex than what has been traditionally described. They showed that the PCL bundles can be divided into anterior and central fibres comprising 80% of the PCL substance and posterior longitudinal and posterior oblique fibres comprising the rest of the PCL.

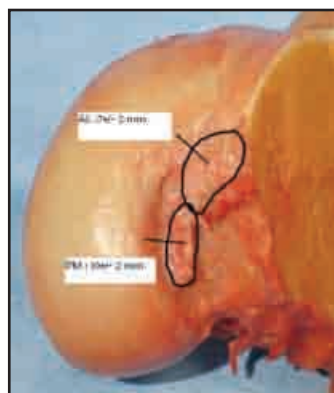


Figure 6: Semi-circular attachment of the posterior cruciate ligament bundles to the roof of the intercondylar notch and medial side wall of the medial femoral condyle

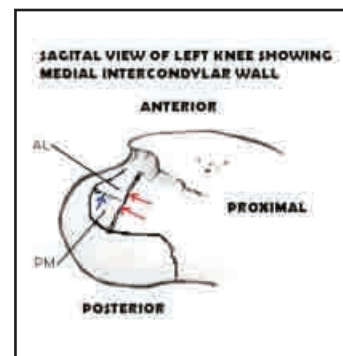

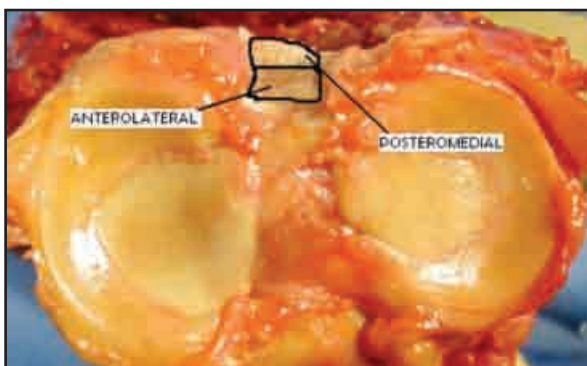

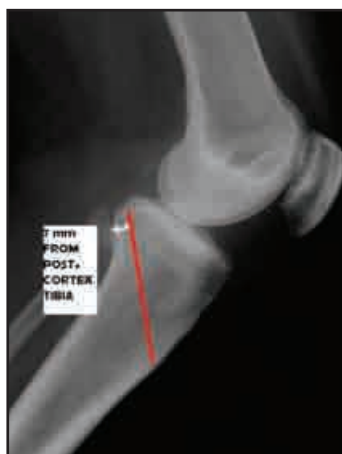
Figure 7: The bony topography of the tibial attachment of the PCL shows a medial intercondylar ridge (red arrows) and a medial bifurcate ridge (blue arrows)



**Figure 8: Bony topography of the attachment of the PCL on the tibial intercondylar area. Note the transverse ridge on the posterior aspect of the tibia marking the posterior attachment of the PCL attachment**



**Figure 9: Tibial plateau with PCL insertions marked in black**

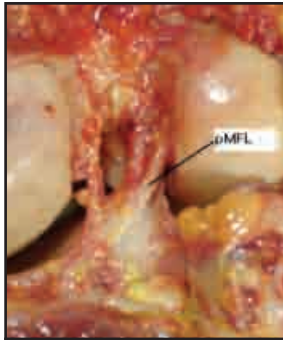


**Figure 10: The correct position for the tibial guidewire is the midpoint of the posterior half of the PCL facet**

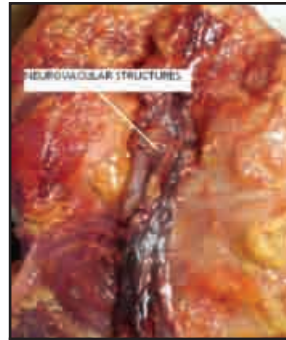In full extension the anterior fibres become fully lax and the central fibres seem to be less lax while the posterior fibres tighten. During flexion up to 90 degrees the anterior and central fibre bundles tighten while the posterior fibres become slightly lax. From 90 to 120 degrees the anterior fibre bundles become slightly less tight while the posterior fibres tighten. The central fibres show no sign of relaxing during this degree of flexion.<sup>12</sup> This does not seem to support the traditional action of the anterolateral and posteromedial bundles. *In vivo* weight-bearing MRI studies showed that from full extension to 90 degrees of flexion the length of the PCL increases 6.5 mm, representing an increase of approximately 22%.<sup>17</sup> The PCL, under joint motion loading conditions, seems to be predominantly non-isometric.<sup>18</sup> *In situ* forces in both the anterolateral and posteromedial bundles did not differ at any flexion angle.<sup>7</sup> These findings and those of other investigators challenge the idea of reciprocal action of the two traditional bundles of the PCL. It seems that there is rather co-dominance of all the fibre bundles.<sup>7,17,18,19</sup> This questions the notion that the anterolateral bundle is the most important bundle to be reconstructed, it being the main factor preventing posterior translation of the tibia with progressive knee flexion.

### Menisco-femoral ligaments

The anterior and posterior menisco-femoral ligaments (MFL) connect the lateral aspect of the medial femoral condyle to the posterior horn of the lateral meniscus (*Figure 11*). The incidence of the anterior and posterior menisco-femoral ligaments vary in the literature.<sup>20,21</sup> Ninety per cent of people have at least one and 31% have both menisco-femoral ligaments. The posterior menisco-femoral ligament is present in 70.4% of people and the anterior menisco-femoral ligament present in 48.2% of people. The anterior menisco-femoral ligament (aMFL) of Humphrey attaches to the femur in the area between the PCL insertion and the articular surface in a position approximately 10h00 in the left knee. It slants across the anterior aspect of the PCL in the flexed knee and is difficult to identify arthroscopically when the anterior cruciate ligament is intact. The aMFL may be identified by the slanting orientation of its fibres which is in contrast to the vertical orientation of the PCL fibres. The femoral insertion of the posterior menisco-femoral ligament (pMFL) of Wrisberg is on the medial sidewall of the femoral intercondylar notch. It is inserted proximal to the posteromedial fibres of the PCL and is therefore superficial to the PCL viewed from posterior. Its attachment is separate to that of the PCL as opposed to the aMFL attachments which blend into the attachment of the PCL. Arthroscopically it is very difficult to identify this ligament as it lies posterior to the PCL. The menisco-femoral ligaments seem to have a reciprocal action, with the aMFL being taut in flexion and the pMFL taut in extension.<sup>22</sup>



**Figure 11: Posterior meniscofemoral ligament**

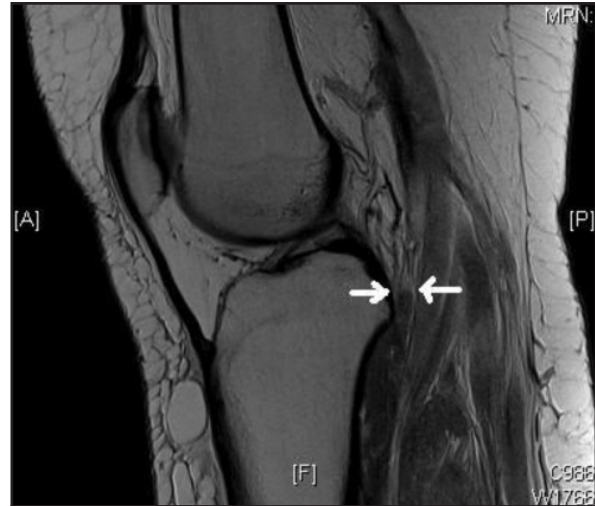

**Figure 12: The close proximity of the neurovascular bundle to the posterior aspect of the tibia**

There is controversy regarding the function of the menisco-femoral ligaments.<sup>21</sup> They seem to regulate the posterior arch of the lateral meniscus in relationship to the femoral condyle thereby preventing impingement of the meniscus during flexion and extension, protecting the meniscus from injury. This is similar to the protection muscle attachments give to capsular structures as shown by Walters and Solomons in their description of the gluteus minimus anatomy.<sup>23</sup> The menisco-femoral ligament also seems to reduce anteroposterior laxity by its function on meniscal congruency as well as by a direct stabilising effect. The ultimate load of the menisco-femoral ligaments is about 30% of the ultimate load of posterior cruciate ligament, with the cross-sectional area approximately 22% of the entire cross-sectional area of the posterior cruciate ligament.<sup>11,22</sup> Because the attachments of the MFL to the relatively mobile posterior horn of the lateral meniscus, it is possible for the PCL to be ruptured and for the MFL to remain intact. This has been shown in experiments on varus and hyperextension injuries in laboratory conditions.<sup>22,24</sup> The intact MFL may act as a splint to keep the injured PCL in position while it heals, and this may be significant in relation to the conservative management of an isolated PCL rupture. A reduced posterior drawer test has been reported by Clancy *et al* in those knees in which the menisco-femoral ligaments remain intact.<sup>25</sup> Mechanically the menisco-femoral ligaments are equal to the posteromedial bundle of the PCL.

### Neurovascular structures

The popliteal artery, popliteal vein and the tibial nerve is directly posterior and slightly lateral to the posterior cruciate ligament regardless of the degree of flexion<sup>26</sup> (Figure 12). The neurovascular structures are held in close proximity to the proximal tibia by the fibrous arch of the soleus muscle. During experimental PCL reconstructions, anatomical dissections showed that the vascular bundle was directly in the path of the tibial guidewire, except in 40% of cases when the knee was held at 100 degrees of flexion.

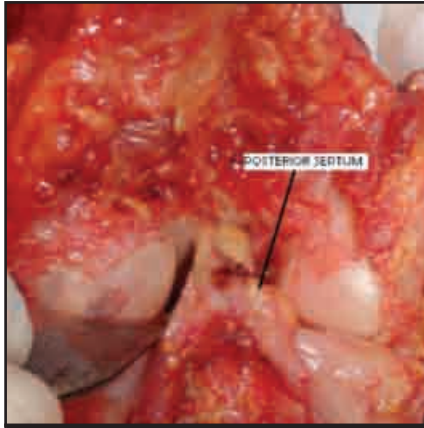


**Figure 13: MRI sagittal image. The space between the white arrowheads shows the sagittal distance between the posterior surface of the tibia and anterior margin of the popliteal artery**

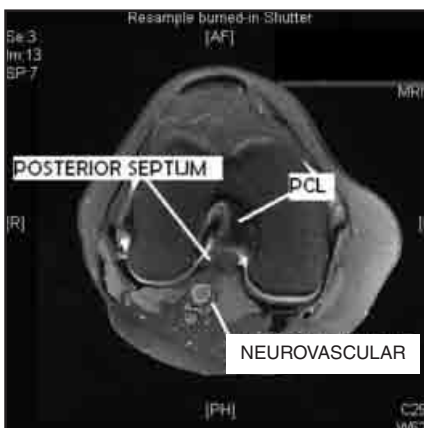
Thus it seems advisable to flex the knee to approximately 100 degrees when drilling the tibial tunnel. The sagittal distance from the insertion of the PCL on the tibia to the neurovascular bundle is a function of knee flexion with the distance usually increasing with flexion (Figure 13). On average at 90 to 100 degrees of flexion, which is the position in which drilling is normally done, the sagittal distance between the posterior tibia (exit point of the guidewire) and neurovascular structure is  $\pm 10$  mm but may be as low as 2 mm. Some authors have found that in 24% of cases the popliteal neurovascular structures may move nearer to the tibia with increased flexion.<sup>27</sup> In practice it seems that flexing the knee to 100 degrees and beyond is a protective measure, either by increasing the distance as well as by changing the anatomic orientation of the vulnerable structures.<sup>26,28</sup>

### Posterior septum

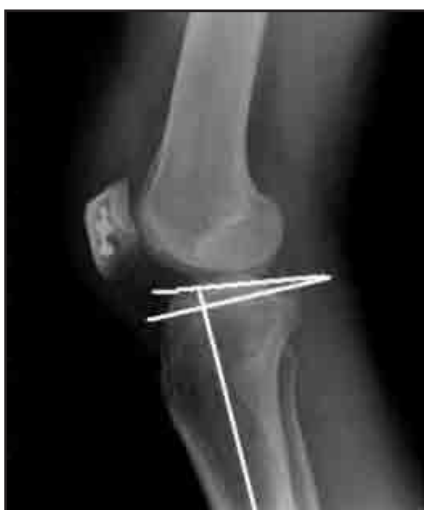The posterior cruciate ligament is intra-articular but extra-synovial. A layer of synovium arising from the posterior capsule envelopes the PCL, creating a posterior septum. The PCL is located at the anterior edge of the septum (Figures 14 and 15). Posteriorly is the posterior joint capsule and superiorly is the posterior aspect of the femur and the intercondylar notch.<sup>29</sup> The middle geniculate artery perforates the joint capsule and runs parallel to the superior edge of the posterior septum. The posterior septum is perforated and debrided as part of the trans-septal approach to the posterior cruciate ligament as described by Ahn *et al*.<sup>29</sup> The sagittal distance from the mid-part of the PCL to the popliteal artery at the level of the posterior septum is approximately 29 mm (18–50 mm).<sup>30</sup>



**Figure 14: Cadaver specimen showing the posterior septum**



**Figure 15: MRI image of the posterior septum and vascular structures**



**Figure 16: Lateral X-ray showing a posterior tibial slope**

---

**By altering the posterior slope one can therapeutically decrease the unfavourable posterior translation of the tibia in a PCL deficient knee**

---

### The vascular supply to the PCL

The middle geniculate artery perforates the posterior capsule running parallel to the superior edge of the synovial septum. It has branches to the synovium around the PCL forming a plexus of vessels supplying the PCL. There is also a potential supply from a branch of the inferior geniculate artery.

### Nerve supply

The nerve supply to the PCL is in accordance with Hilton's law which states that a joint is supplied by the nerves to the muscles that cross the joint.<sup>30</sup> The tibial and obturator nerve has posterior articular branches to the posterior capsule. These branches perforate the posterior capsule to reach the PCL.<sup>31,32</sup> Superficial sub-synovial axons are found in the PCL. Four types of receptors are found in the PCL, namely Ruffini slow adapting M-receptors, Pacinian fast adapting M-receptors, Golgi-like tension receptors and pain receptors.<sup>32,33</sup>

### Tibial slope

Normally the proximal tibial articular surface has a caudal inclination (*Figure 16*). The average is  $10 \pm 3$  degrees. During axial loading the tibia undergoes anterior translation of between 2 to 5 mm due to the slope. This happens in both the PCL intact and deficient knee. When the tibial slope is increased by a 5 mm anterior-based osteotomy, the posterior translation of the tibia in 90 degrees of flexion is decreased by 50%.<sup>34</sup> Thus the tibial slope plays an assistive role to the PCL. By altering the posterior slope one can therapeutically decrease the unfavourable posterior translation of the tibia in a PCL deficient knee.

### Conclusion

The posterior cruciate ligament needs to be seen as part of a complex anatomic system including the menisci, menisco-femoral ligaments, the posterolateral corner, posteromedial structures and bony architecture. Together they play an important role in the stability and clinical function of the knee. Understanding the anatomy is the departure point for successful conservative or surgical treatment.

### Acknowledgement

I would like to thank Smith & Nephew for the use of their cadaver laboratory, as well as Philippa Amos from Smith and Nephew for help with the dissection of the knees.

*No benefits of any form have been derived from any commercial party related directly or indirectly to the subject of this article.*

## References

1. Walters J. Isolated posterior cruciate ligament injury : does surgery improve the outcome? A discussion of the literature. *SA Orthopaedic Journal* 2006 Feb;**5**(1):8–14.
2. Kumagai M, Mizumo Y, Matteschi SM, Elias JJ, Cosgarca AJ, Chao EY. Posterior cruciate ligament rupture alters in vivo knee kinematics. *Clin Orthop* 2002;**345**:241-8.
3. Vogrin T, Giffen JR, Woo SL, Fu FH, Harner CD. Biomechanics of the posterior cruciate deficient knee. *Techniques in knee surgery* 2001;**16**(2):109-18.
4. Race A, Amis AA. Loading of the two bundles of the posterior cruciate ligament: An analysis of bundle function in AP drawer. *J Biomech* 1996;**29**:873-9.
5. Sekiya JK, Whiddon DR, Zehms CT, Miller MD. A clinical relevant assessment of posterior cruciate ligament and posterolateral corner injuries. Evaluation of isolated and combined deficiency. *J Bone Joint Surg (Am)* 2008;**90**:1621-7.
6. Le Prade RF, Tso A. Force measurement on fibular collateral ligament, popliteofibular ligament and popliteus tendon to applied loads. *Am J Sports Med* 2004;**32**:1695-701.
7. Mauro CS, Sekiya JK, Stabile KJ, Haemmerle MJ, Harner CD. Double bundle PCL and posterolateral corner reconstruction components are codominant. *Clin Orthop* 2008;**466**:2247-5.
8. Goodes ES, Stowers SF, Noyes FR. Limits of movement in the human knee. Effect of sectioning the posterior cruciate ligament and posterolateral structures. *J Bone Joint Surg (Am)* 1988;**70**:88-97.
9. Davis DK, Goltz DH, Fithian DC, D'Limia D. Anatomical posterior cruciate ligament transplantation. A biomechanical analysis. *Am J Sports Med* 2006; **34**:1126-33.
10. Shybar MJ, Warren RP. The effect of sectioning the posterior cruciate ligament and posterolateral complex on the articular contact pressure within the knee. *J Bone Joint Surg (Am)* 1993;**75**:694-9.
11. Harner CD, Xerogeanes JW, Livesay GA, Carlin GJ, Smith BA, Kusaiyama T, Kashivraguchi S, Woo SL. The human posterior cruciate ligament complex: An interdisciplinary study. *Am J Sports Med* 1995;**23**:736-45.
12. Makris CA, Georgoulis AD, Papageorgiou CP, Saucacos PN. Posterior cruciate ligament architecture: Evaluation under microsurgical dissection. *Arthroscopy* 2000; **16**(6):627-32.
13. Edwards A, Bull AMJ, Amis AA. The attachment of the fibre bundles of the posterior cruciate ligament: An anatomical study. *Arthroscopy* 2007;**23**(3):284-90.
14. Lopes OV, Ferretti M, Shen W, Ekdahl M, Smolinski P, Fu FH. Topography of the femoral attachment of the posterior cruciate ligament. *Bone Joint Surgery (Am)* 2008;**90**:249-55.
15. Sheps DM, Otto D, Fernhout M. The anatomic characteristics of the tibial insertion of the posterior cruciate ligament. *Arthroscopy* 2005;**21**(7):820-5.
16. Moorman CT, Zane MSM, Bansai S, Cina SJ, Wickiewicz TL, Warren RF, Kaseta MK. Tibial insertion of the posterior cruciate ligament: A sagittal plane analysis using gross, histological and radiographic methods. *Arthroscopy* 2008;**24**(2):269-75.
17. De Frate LE, Gill TJ, Li G. In vivo function of the posterior cruciate ligament during weightbearing flexion. *Am J Sports Med* 2004;**32**(8):1923-8.
18. Covey DC, Sapega AA, Sherman GM. Testing for isometry during reconstruction of the posterior cruciate ligament. Anatomic and biomechanical considerations. *Am J Sports Med* 1996;**24**(6):740-6.
19. Ahmad CS, Cohen A, Levine WN, Gardner TR, Ateshian GA, Mow C. Codominance of the individual posterior cruciate ligament bundles. *Am J Sports Med* 2003;**31**(2):221-5.
20. Heller L, Langman J. The meniscofemoral ligaments in the human knee. *J Bone Joint Surg (Br)* 1964;**46**:307-13.
21. Gupte CM, Bull AMJ, Thomas R de W, Amis AA. A review of the function and biomechanics of the menisco-femoral ligaments. *Arthroscopy* 2003;**19**(2):161-71.
22. Moran CJ, Poyton AR, Moran R, O'Brien M. Analysis of meniscofemoral ligament tension during knee motion. *Arthroscopy* 2006;**22**(4):362-6.
23. Walters J, Solomons M. Gluteus minimus: Observations on its insertion. *Journal of Anatomy* 2001 Feb;**198**:239-42.
24. Amis AA, Gupte CM, Bull AMJ, Edwards A. Anatomy of the posterior cruciate ligaments and the menisco-femoral ligaments. *Knee Surg Sports Traumatol Arthrosc* 2006;**14**:257-63.
25. Clancy WGJ, Shelbourne KD, Zoellner GB. Treatment of knee joint instability secondary to rupture of the posterior cruciate ligament. *J Bone Joint Surg (Am)* 1983;**65**:310-22.
26. Matara MJ, Sethi NS, Totty WG. Proximity of the posterior cruciate ligament insertion as a function of the knee flexion angle: Implications for posterior cruciate ligament reconstruction. *Arthroscopy* 2000;**16**(8):796-804.
27. Shetty AA, Tindale AJ, Querski F, Divekar M, Fernando KWK. The effect of knee flexion on the popliteal artery and its clinical significance. *J Bone Joint Surg (Br)* 2003;**85**:218-22.
28. Zaidi SHA, Cobb AG, Bentley G. Danger to the popliteal artery in high tibial osteotomy. *J Bone Joint Surg (Br)* 1995;**7**:384-6.
29. Ahn JH. Posterior trans-septal approach for arthroscopic surgery of the knee. *Arthroscopy* 2000;**16**:774-9.
30. Kramer DE, Bank MS, Casio BM, Cosgarea AJ. Posterior knee arthroscopy: Anatomy, technique, application. *J Bone Joint Surg (Am)* 2006;**88**:110-21.
31. Horner G, Dellor AL. Innervation of the human knee joint and implications for surgery. *Clin Orthop* 1994;**301**:221-6.
32. Hirasawa Y, Okajima S, Ohta M, Tokioka T. Nerve distribution to the human knee joint anatomical and immunohistological study. *International Orthopaedics (Sicot)* 2004;**24**:1-4.
33. Kennedy JC, Alexander IJ, Hayes KC. Nerve supply of the human knee and its importance: *Am J Sports Med* 1982;**10**(6):329-34.
34. Giffen JR, Stabile KJ, Zantop T, Vogrin TM, Woo SL, Harner CD. Importance of tibial slope for stability of the posterior cruciate ligament deficient knee. *Am J Sports Med* 2007;**35**(9):1443-9.